


How to Read an Athlete's ECG

- Sanjay Sharma BSc (Hons), MD, FRCP, FESC

Athlete's EKG



Vagotonia

Sinus bradycardia
Sinus arrhythmia
First degree AVB
ST-elevation
Tall T waves

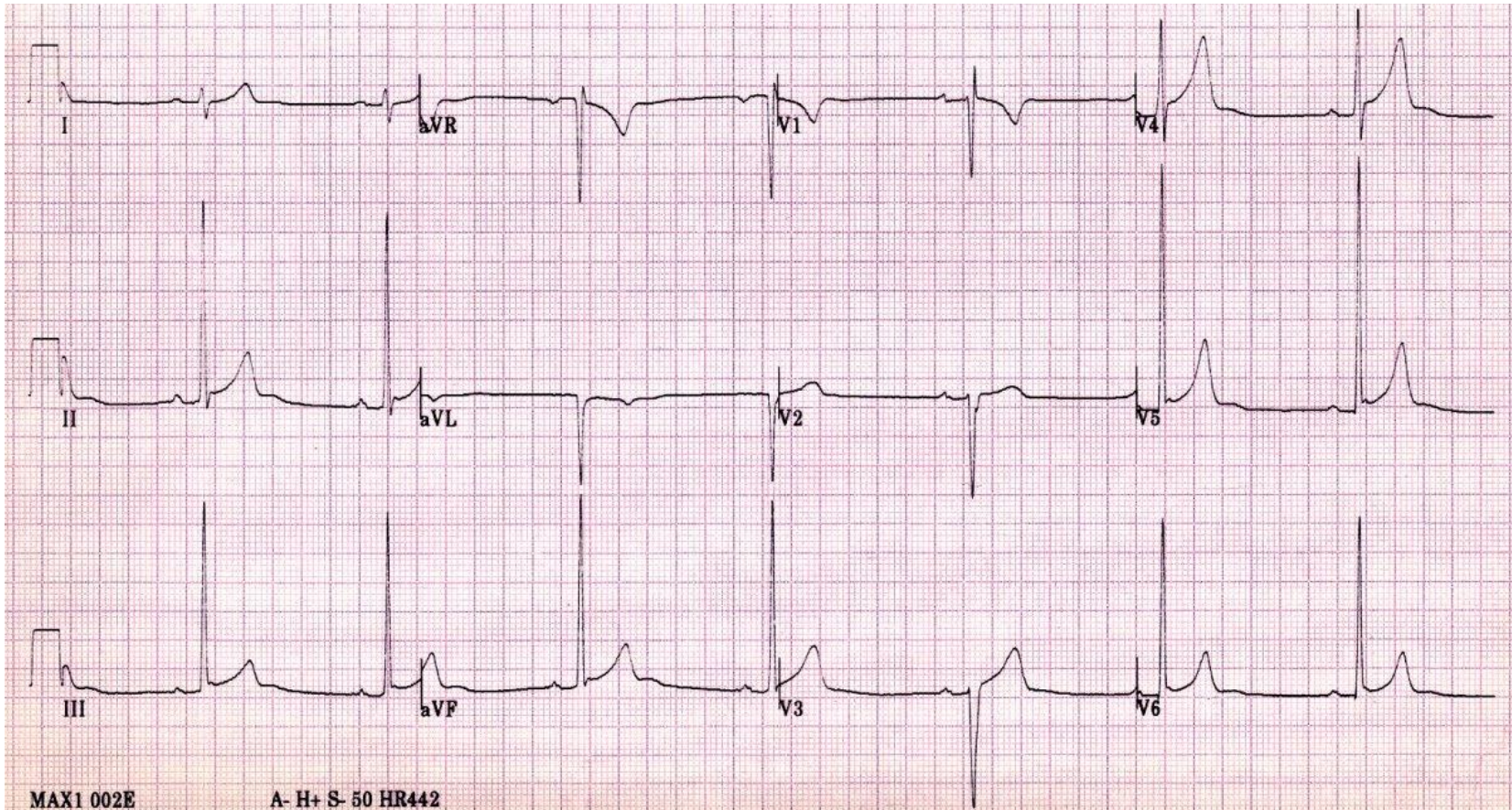
Increased chamber size

Left ventricular hypertrophy
Incomplete RBBB
Left atrial enlargement
Right atrial enlargement

(Group 1)
common (up to 80%)

- Sinus bradycardia
- First degree AV block
- Notched QRS in V1 or incomplete RBBB
- Early repolarization
- Isolated QRS voltage criteria for left ventricular hypertrophy

This is an EKG from a 23 year old asymptomatic rower. Physical examination normal. BP 110/70 mm Hg. How would you interpret this EKG.

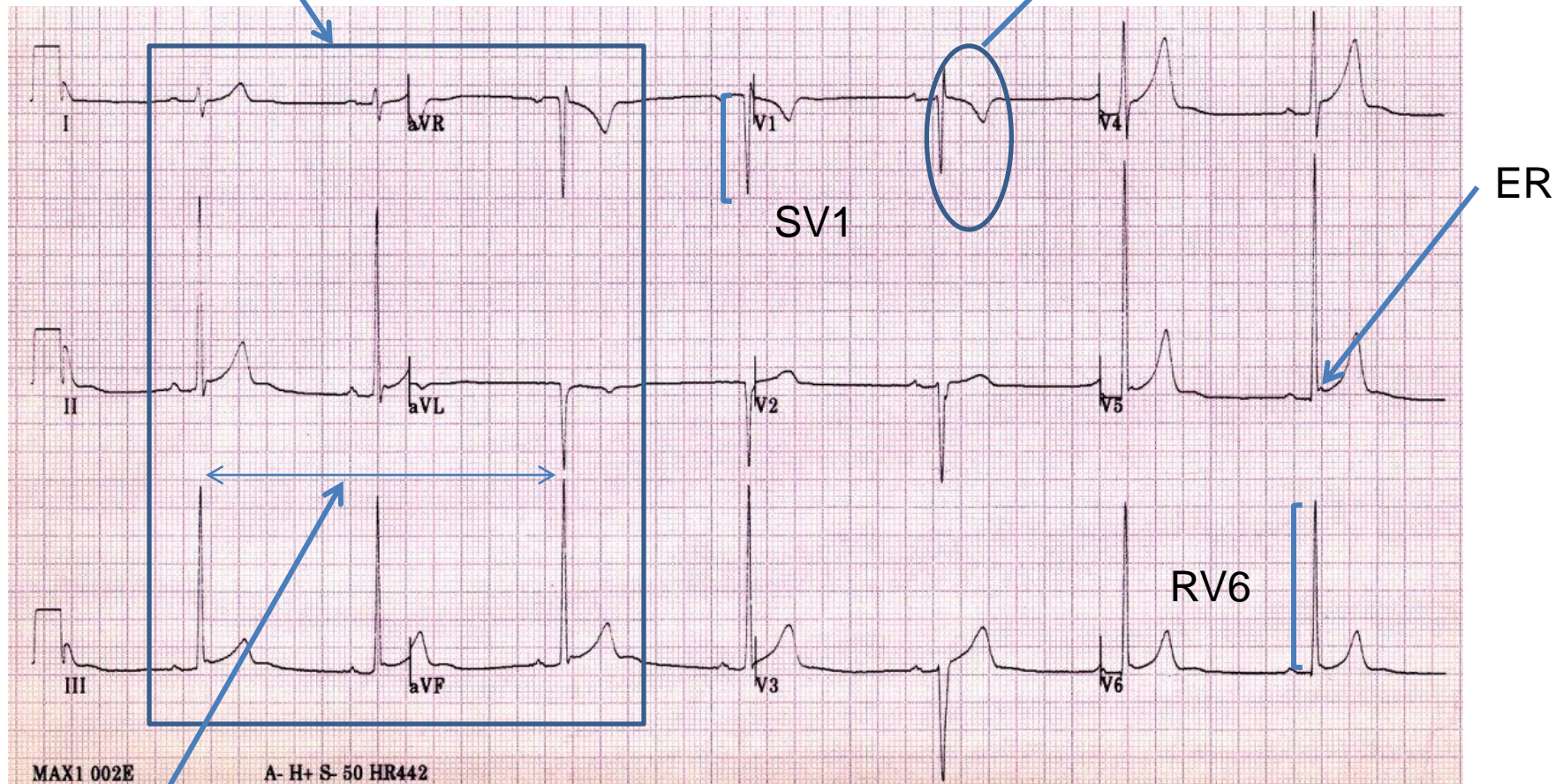


Message 1

Isolated Sokolow-Lyon voltage criterion for LVH is common in male athletes and does not warrant further investigation.

Right axis deviation

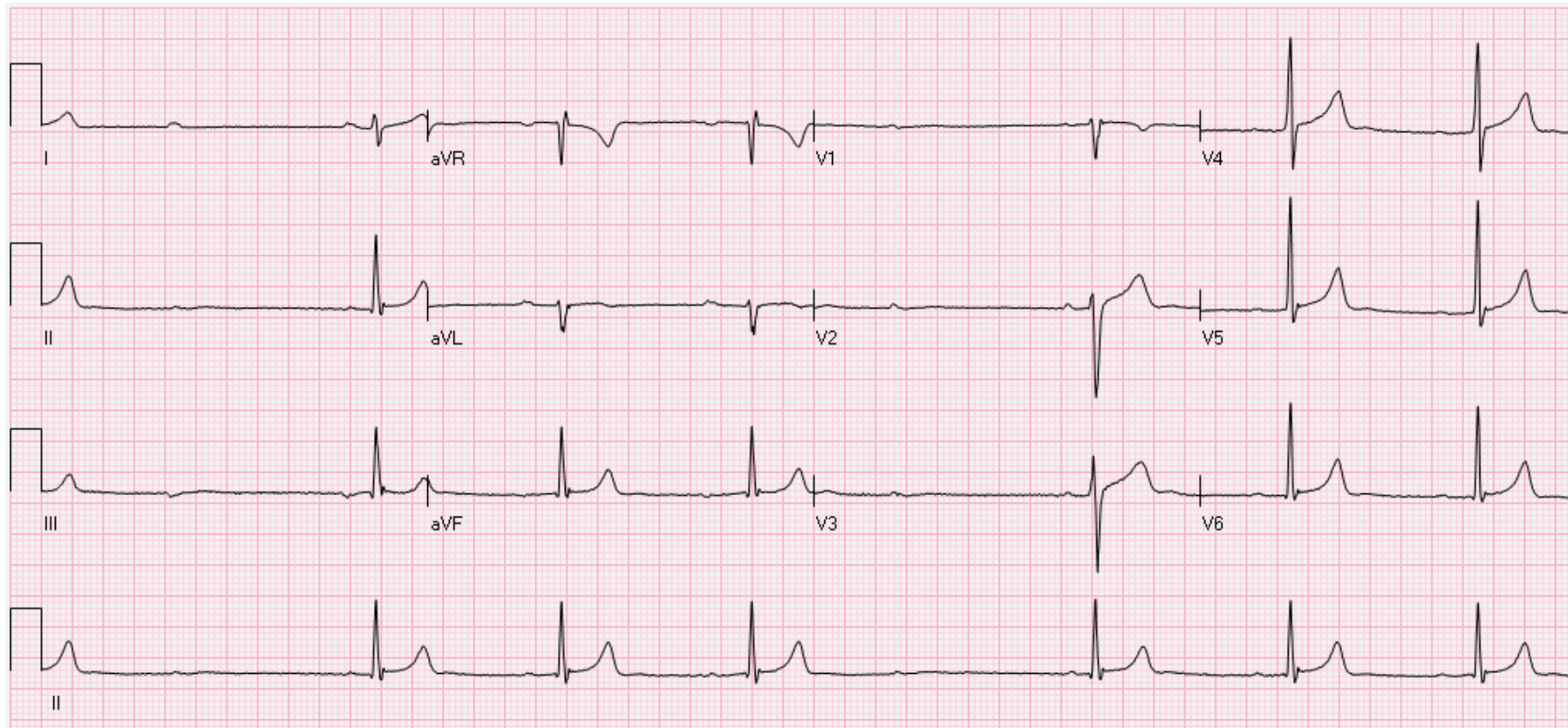
Incomplete RBBB



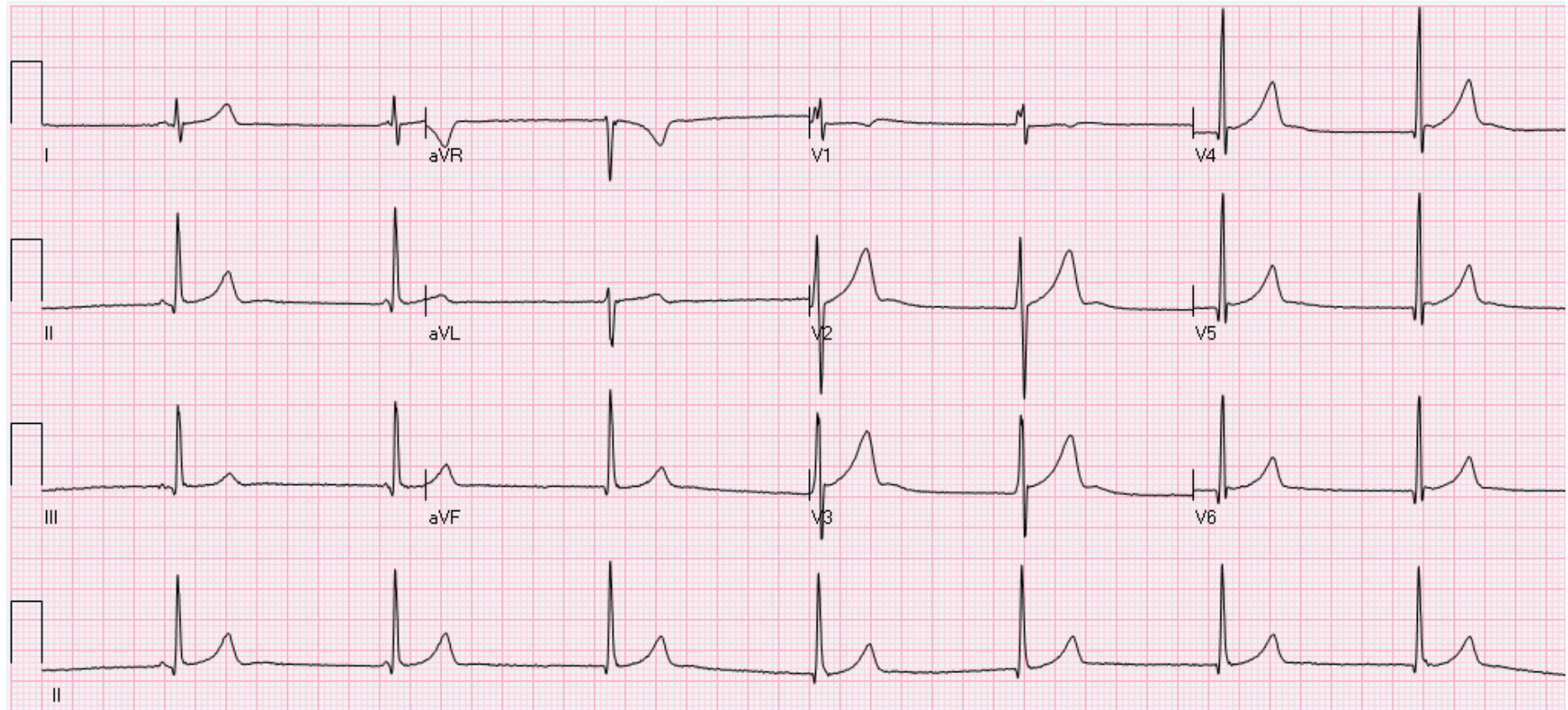
Sinus bradycardia 45 bpm

$SV1 + RV6 > 3.5 \text{ mV} = \text{LVH}$

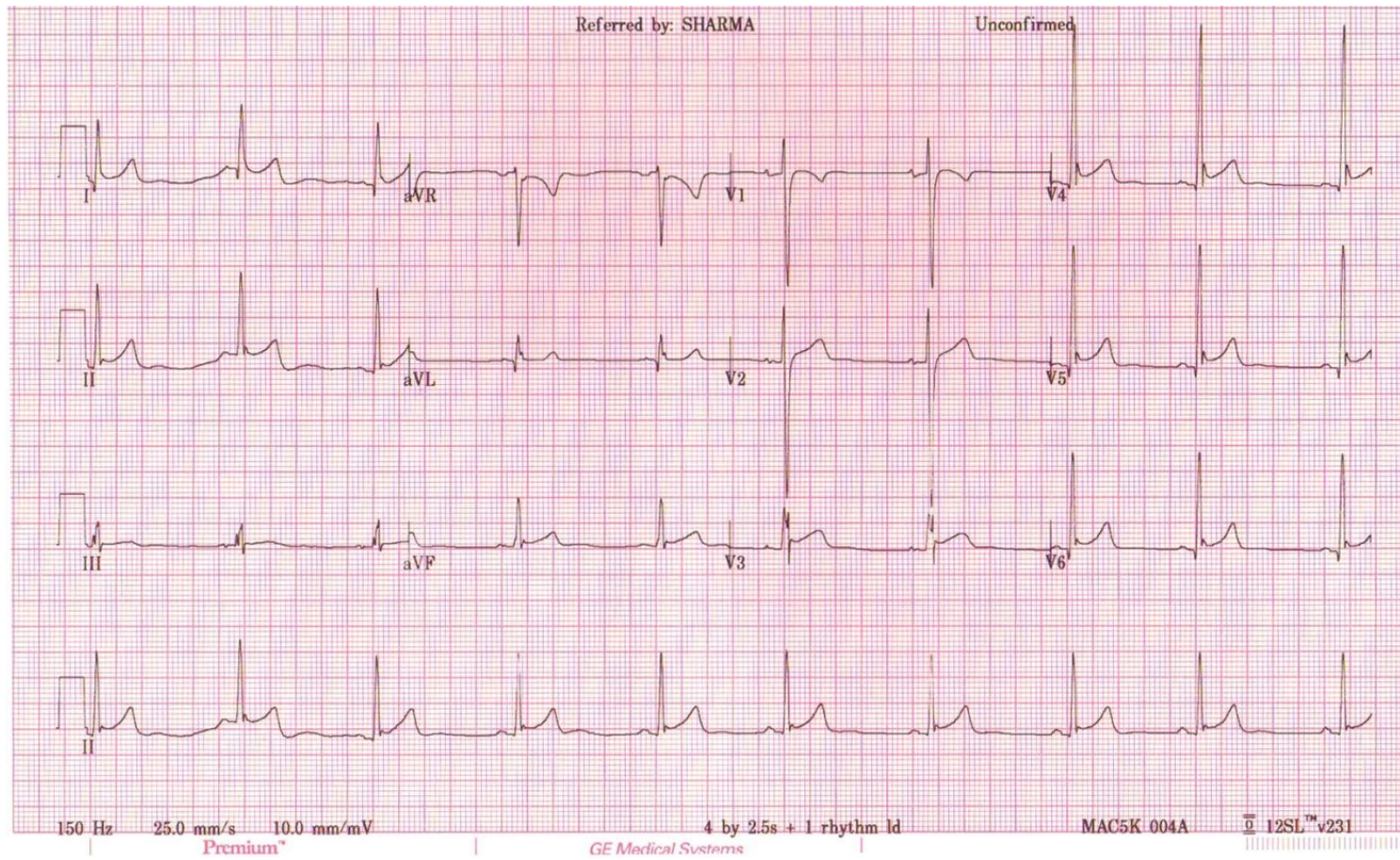
This is an EKG from an asymptomatic cyclist. What would you do next?



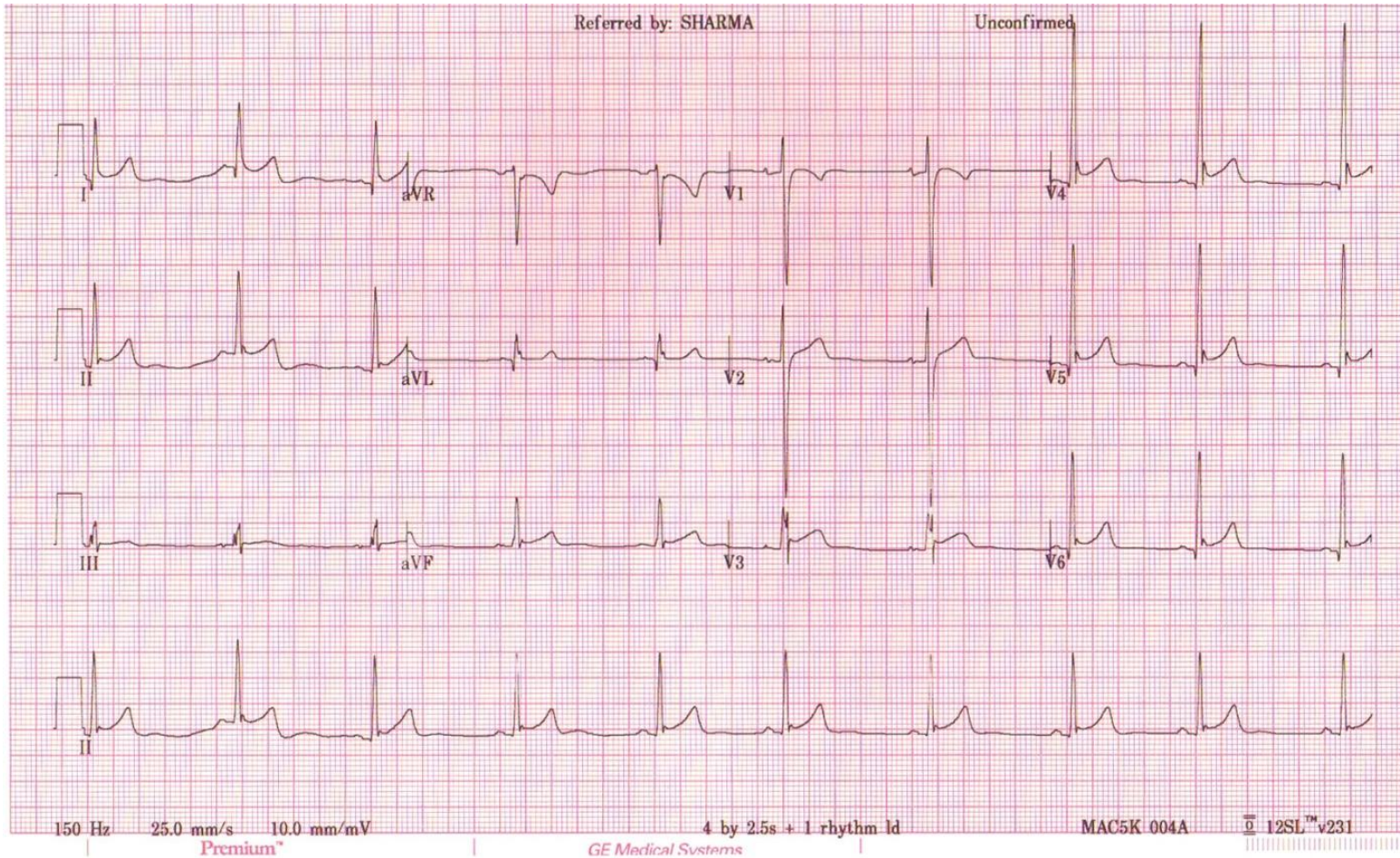
This athlete is asymptomatic. What would you do next?



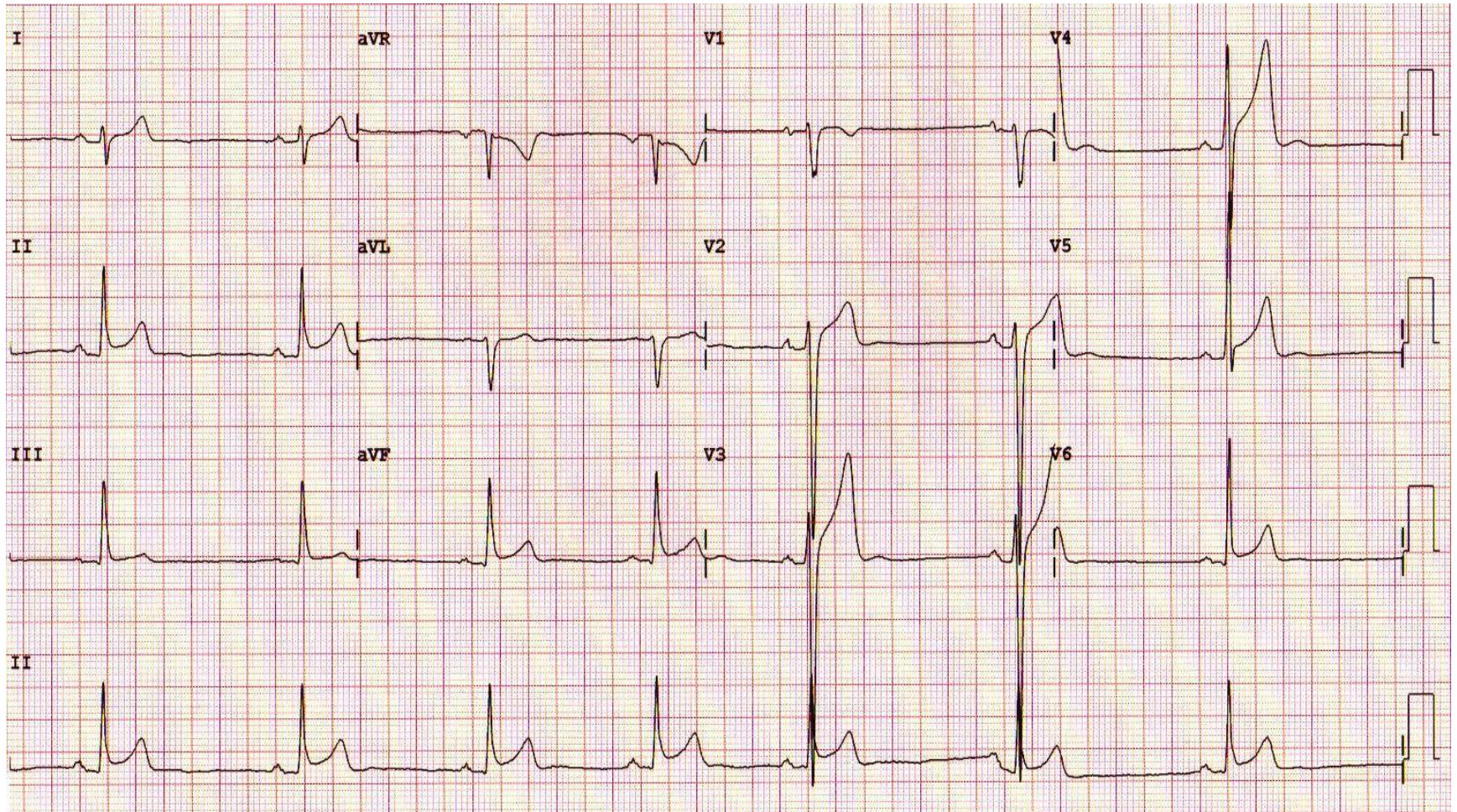
This soccer player has experienced transient dizziness on two occasions after a hard game a football. He has never lost consciousness. There is no relevant family history. Physical examination and echocardiography were normal.



Early Repolarisation Pattern



Early Repolarisation in Athletes





Circulation
Office
http:

ORIGINAL ARTICLE

Long-Term Outcome Associated with Early Repolarization on Electrocardiography

Jani T. Tikkanen, B.S., Olli Anttonen, M.D., M. Juhani Junttila, M.D.,
Aapo L. Aro, M.D., Tuomas Kerola, M.D., Harri A. Rissanen, M.Sc.,

Incidence and Clinical Significance

Raphael Rosso, MD,* Evyatar
Melvin M. Scheinman, M.D.
Karin Heller, MD,* Michalek

The NEW ENGLAND JOURNAL of MEDICINE

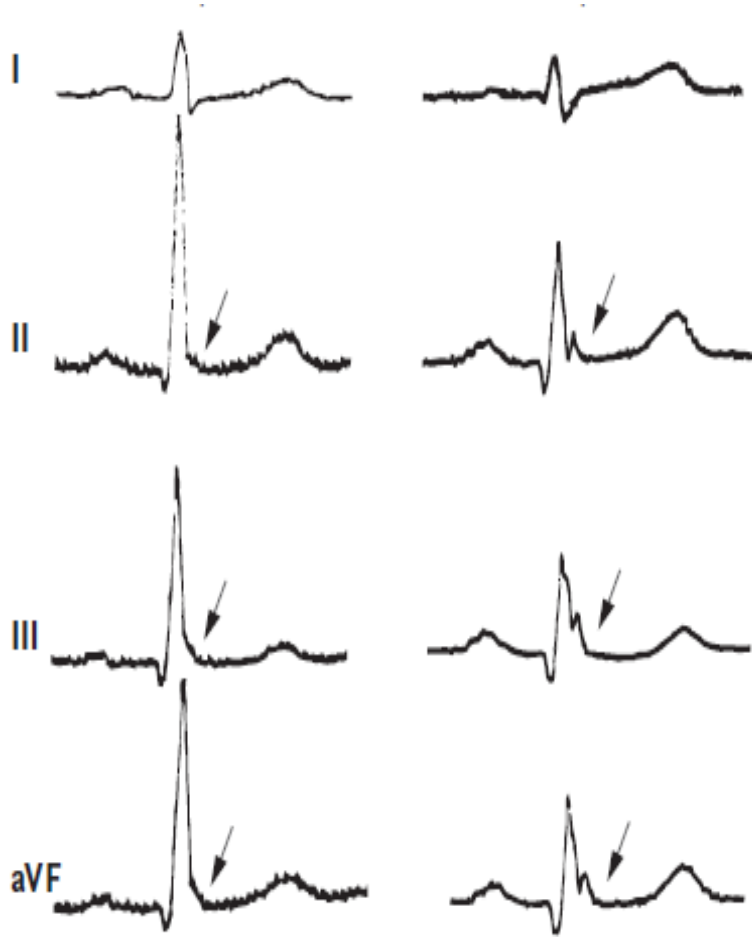
Early repolarization electrocardiography pattern with unexplained syncope during training in a young black African non-elite athlete: An accidental finding?

Aimé Bonny^{1,2}, Ivo Ditah³, Walid Amara⁴, Brahim Hamdaoui⁵,
Robert Frank², Jean-Yves Le Heuzey¹

d

r, M.D.,
I.D.,

EARLY REPOLARISATION PATTERN



2-6% in general population

ERP in the inferior or lateral leads identified in 31% of cases with aborted idiopathic VF (Haisuguerre NEJM 2008)

J-point elevation > 0.2 mV in the inferior leads increased risk almost 3-fold (Tikkanen NEJM 2009)

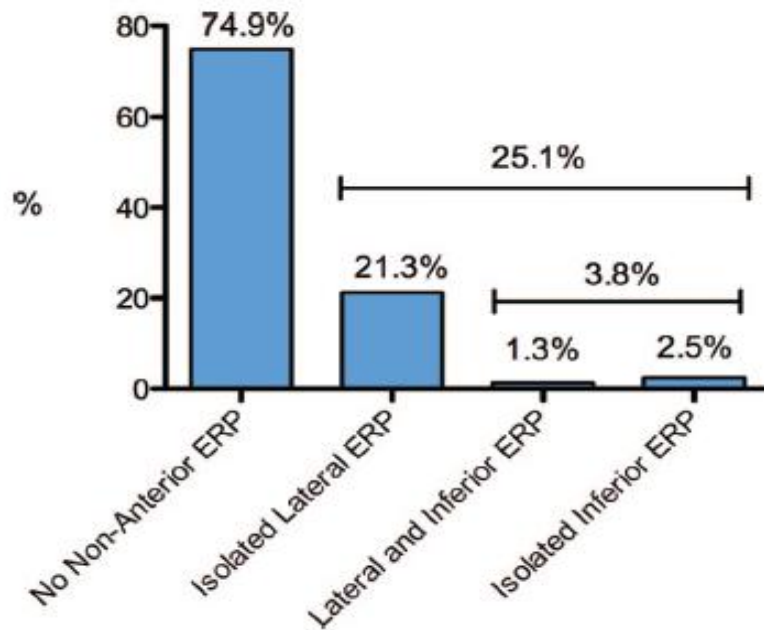
Deaths occurred in those with horizontal or depressed ST segments



Early Repolarization Pattern in Competitive Athletes : Clinical Correlates and the Effects of Exercise Training

Peter A. Noseworthy, Rory Weiner, Jonathan Kim, Varsha Keelara, Francis Wang, Brant Berkstresser, Malissa J. Wood, Thomas J. Wang, Michael H. Picard, Adolph M. Hutter, Jr, Christopher Newton-Cheh and Aaron L. Baggish

Circ Arrhythm Electrophysiol 2011;4:432-440; originally published online May 4, 2011; DOI: 10.1161/CIRCEP.111.962852



Common in:

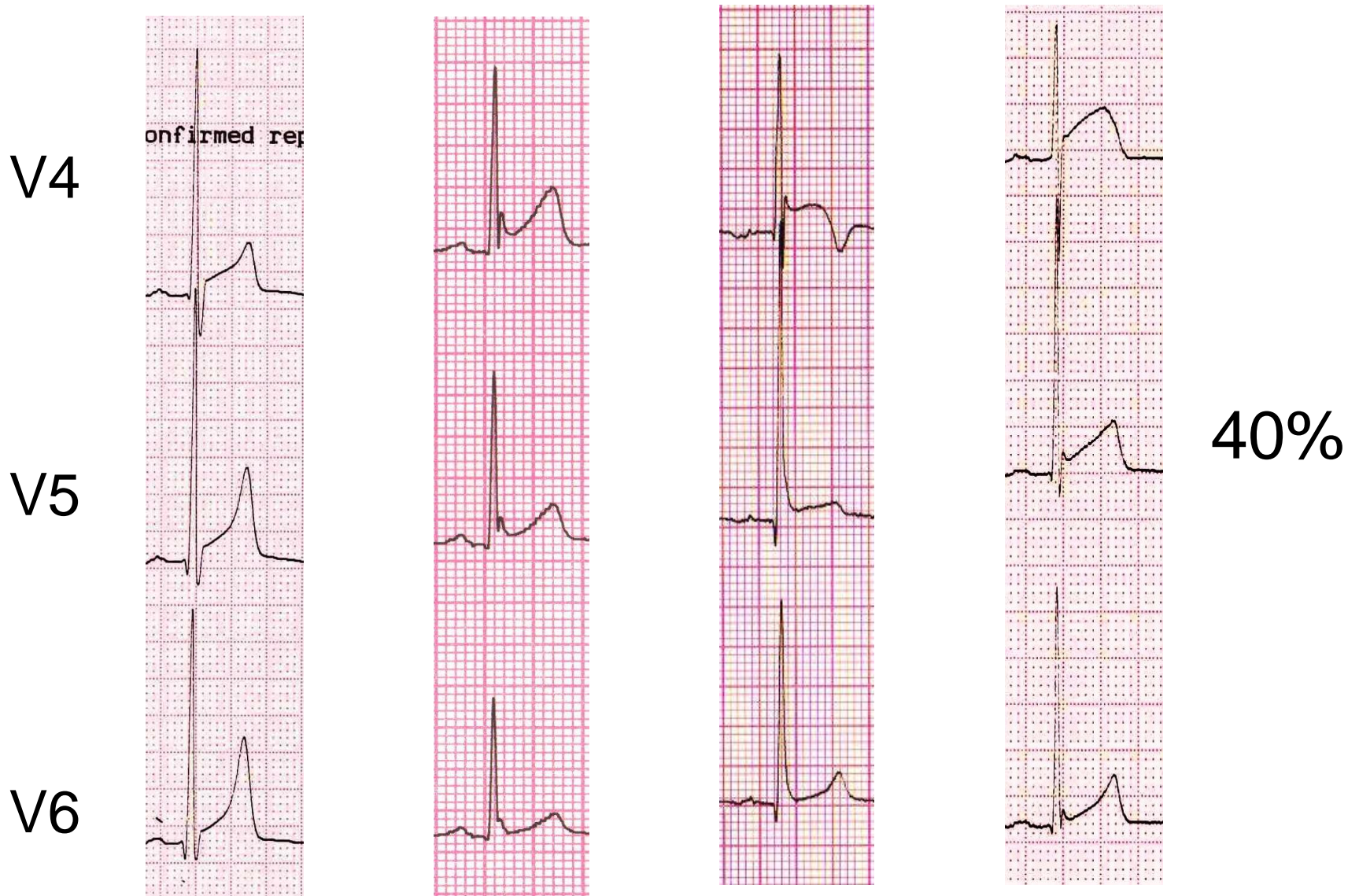
Male athletes

Black athletes

Endurance athletes

Athletes with voltage
criterion for LVH

ER Pattern in Black Athletes



Message 2

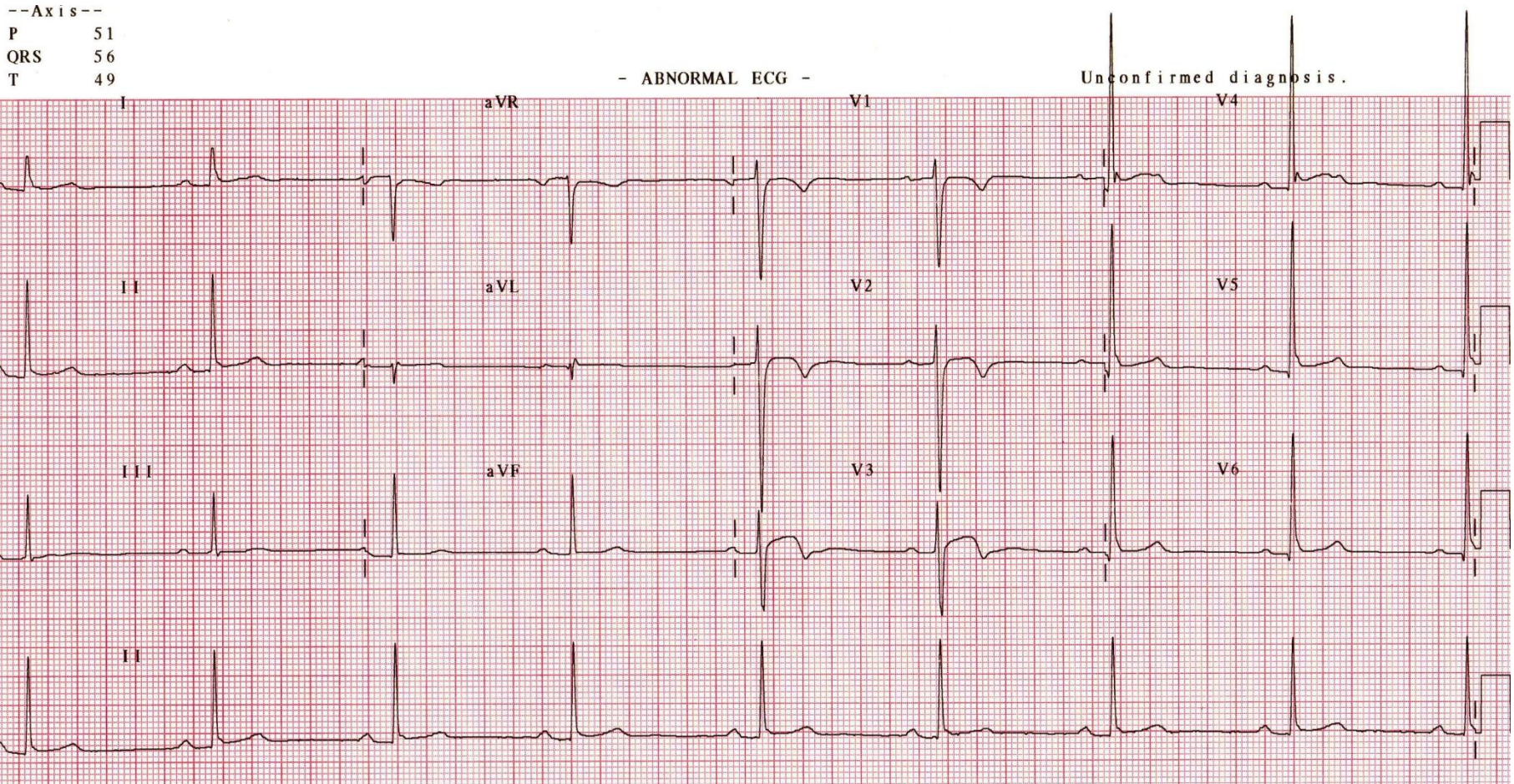
The early repolarisation pattern accompanied by concave ST segment elevation is identified in 25-40% of highly trained athletes.

More common in males, black athletes and those with sinus bradycardia.

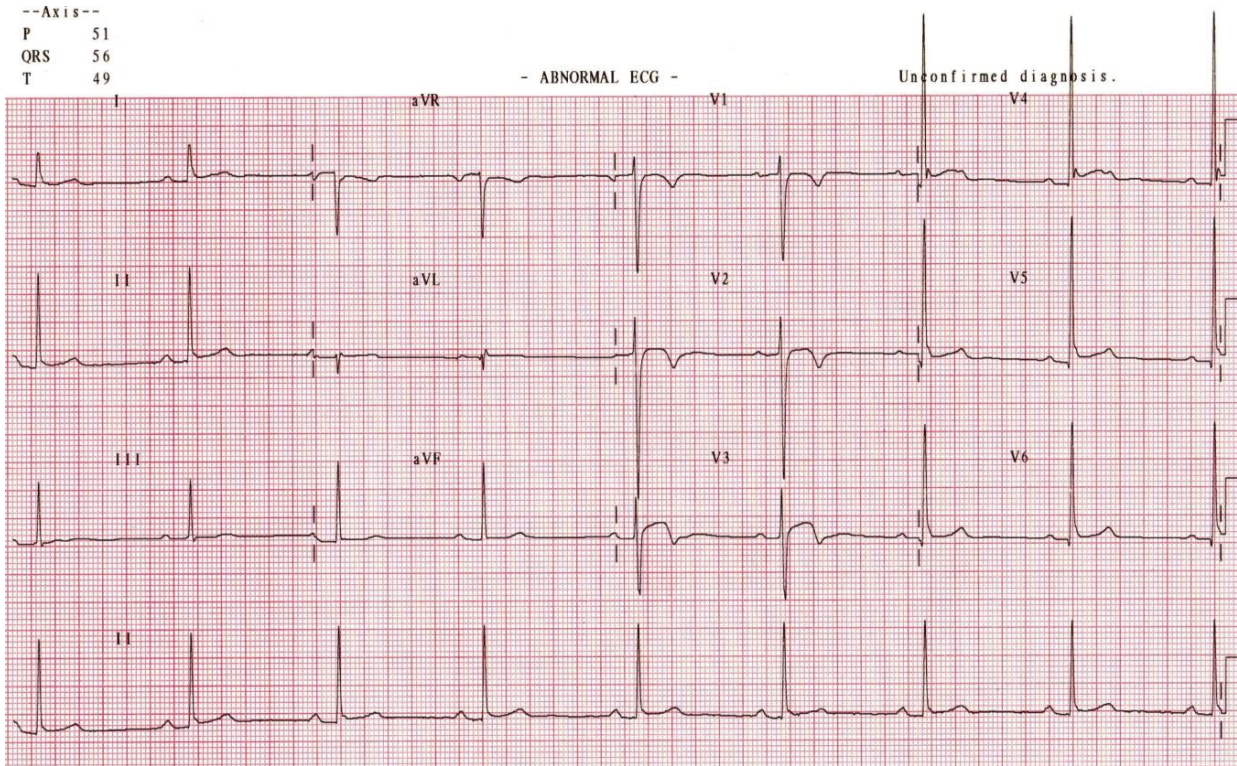
(Group 2)
Uncommon (< 5%)

- T-wave inversion
- ST-segment depression
- Pathological Q waves
- Left atrial enlargement
- Left axis deviation/left anterior hemiblock
- Right axis deviation/left posterior hemiblock
- Right ventricular hypertrophy
- Complete LBBB or RBBB
- Long or short QT interval
- Brugada-like early repolarization
- Ventricular arrhythmias

This is the EKG from an asymptomatic 15 year old tennis player. Echocardiography is normal. Would you perform any further investigations at this time?



Juvenile ECG Pattern (T Wave Inversions in Leads V1-V4 in Caucasian athletes)



Age < 14 years

8.4-9.3%

Age ≥ 14 years

1.4%

Age > 16

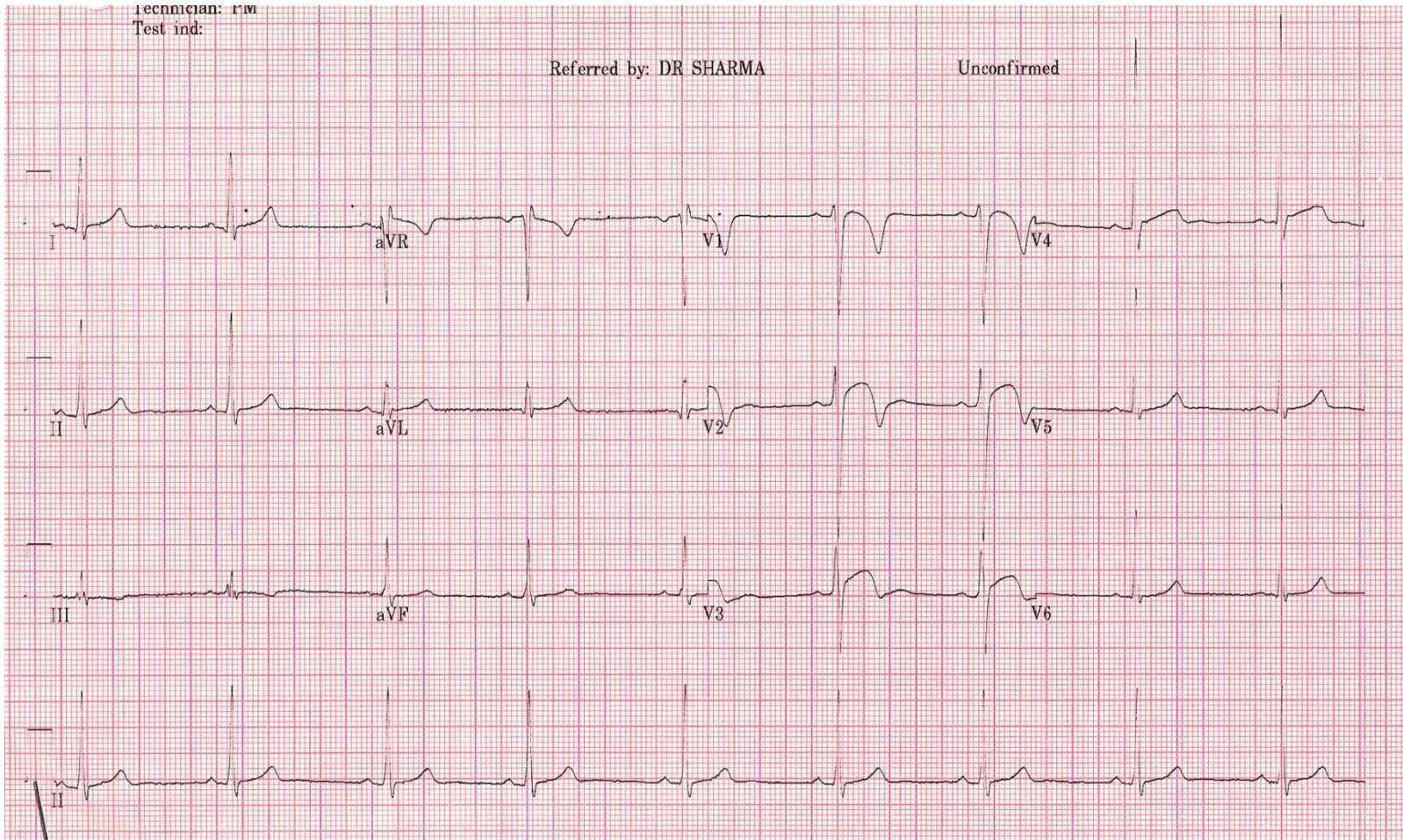
0.2% beyond V2

Message 3

The juvenile ECG pattern (T wave inversion in leads V1-V3) is acceptable up to age 16 years old.

T wave inversion beyond V2 after age 16 warrants further assessment in Caucasian athletes.

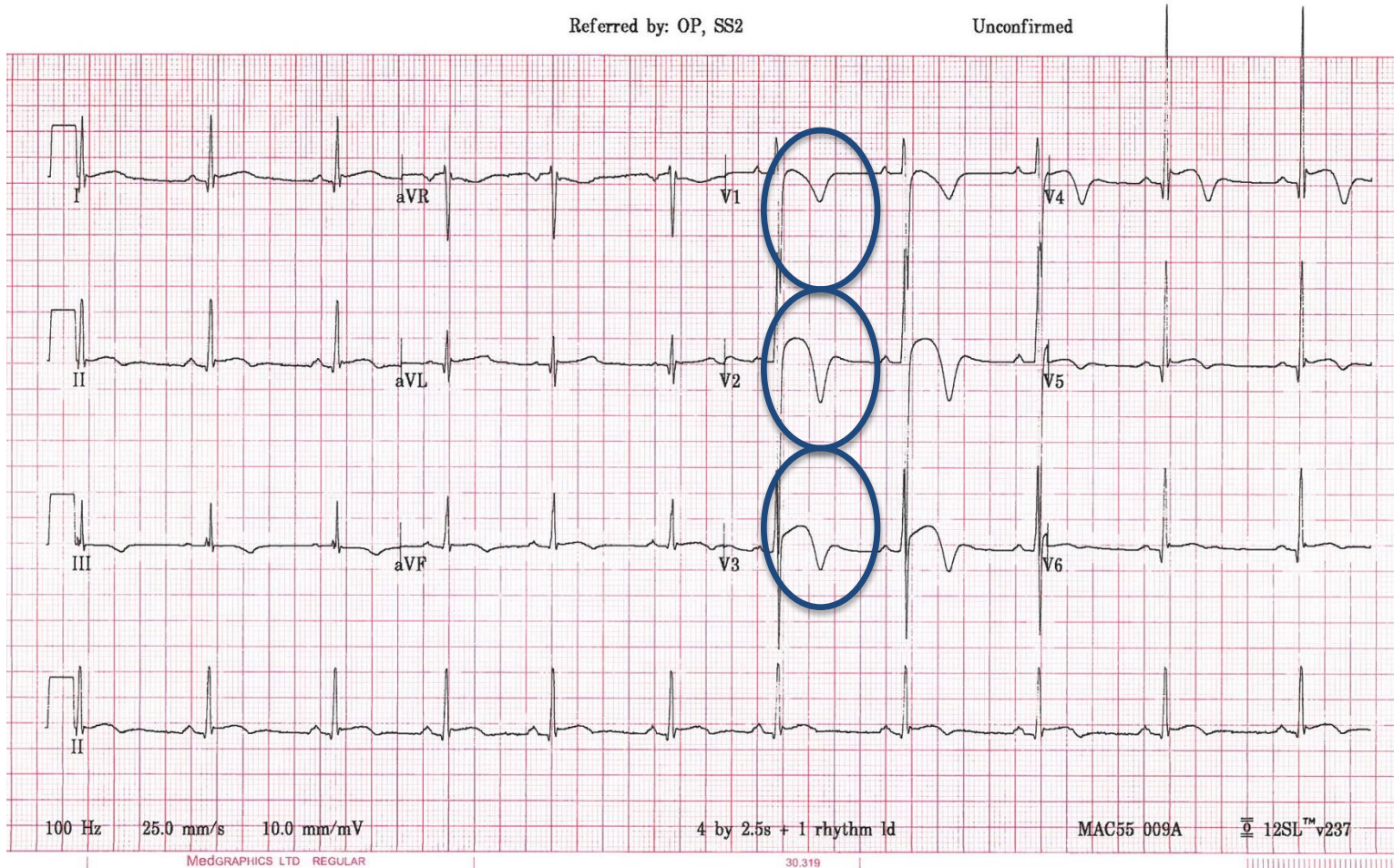
EKG from an Asymptomatic Black Soccer Player. Normal or abnormal?



Black athlete's EKG

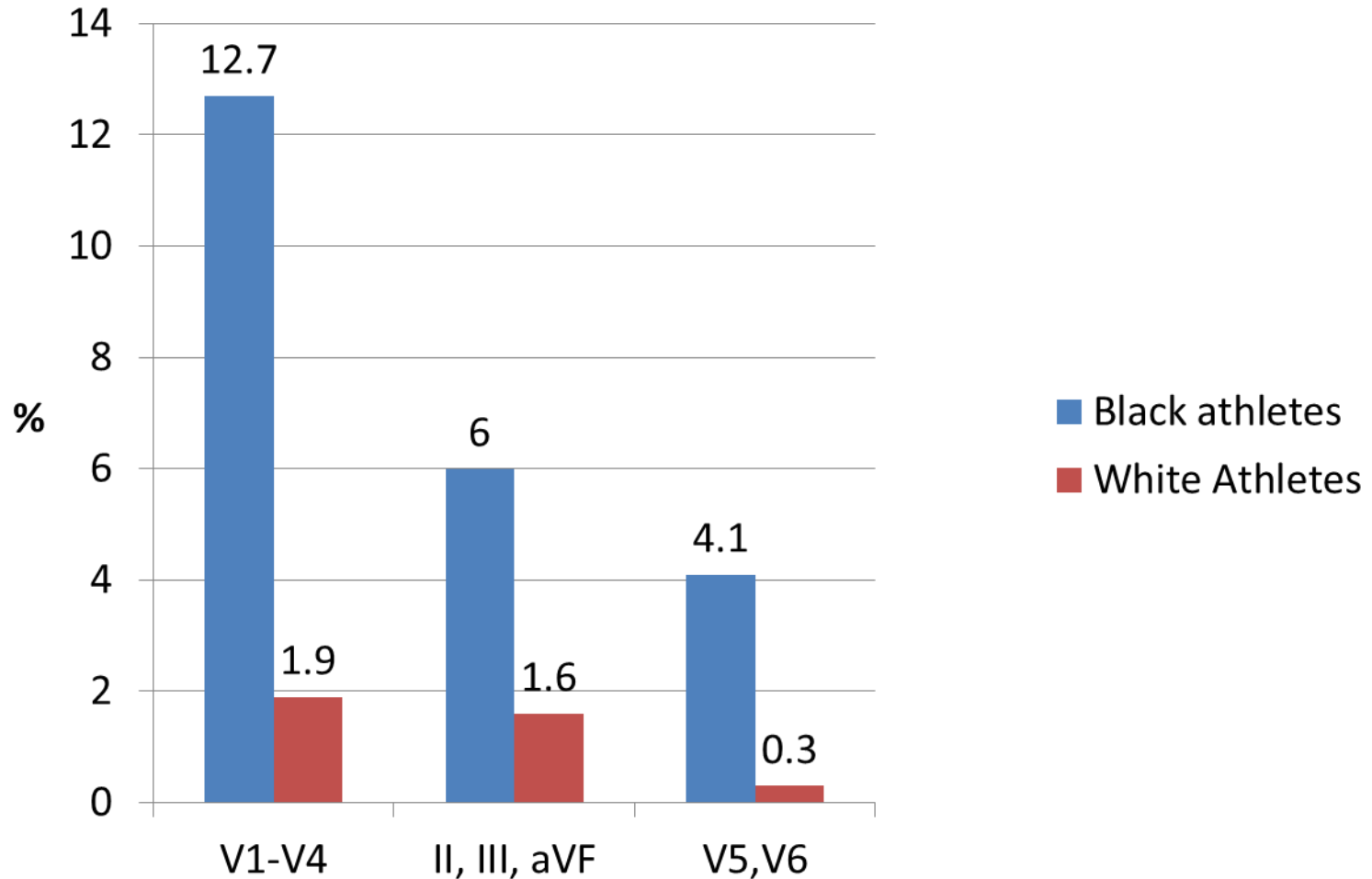
Referred by: OP, SS2

Unconfirmed

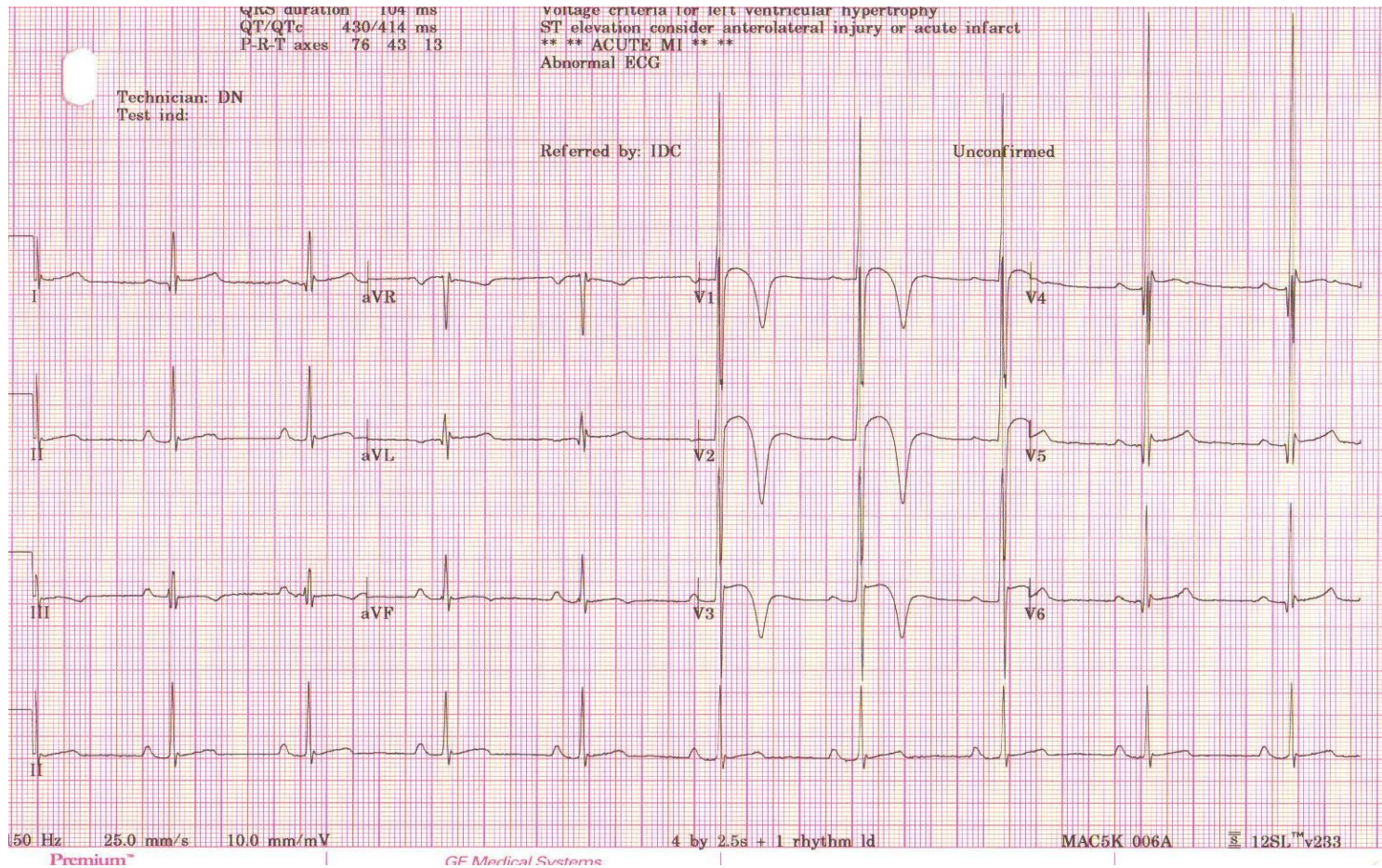


The prevalence, distribution, and clinical outcomes of electrocardiographic repolarization patterns in male athletes of African/Afro-Caribbean origin

Michael Papadakis^{1,2}, Francois Carre³, Gaelle Kervio⁴, John Rawlins^{1,2}, Vasileios F. Panoulas², Navin Chandra^{1,2}, Sandeep Basavarajaiah², Lorna Carby², Tiago Fonseca², and Sanjay Sharma^{1,2*}



Marked Repolarisation Changes

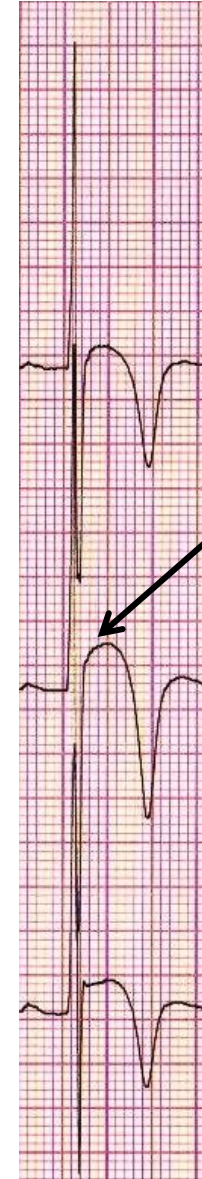
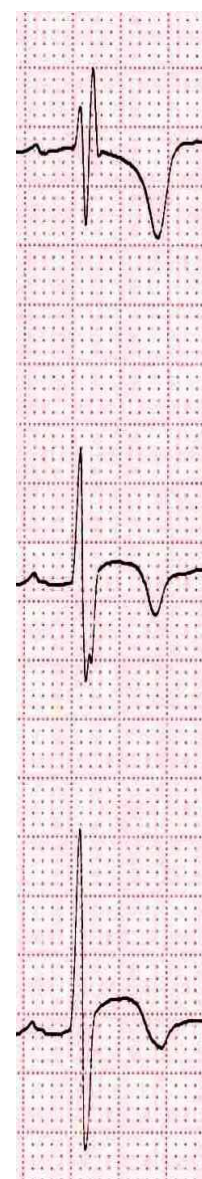
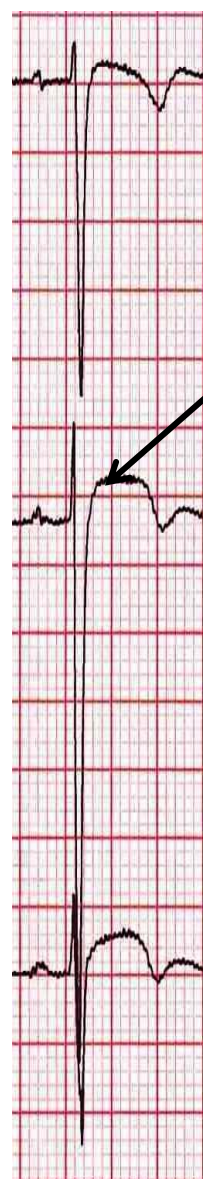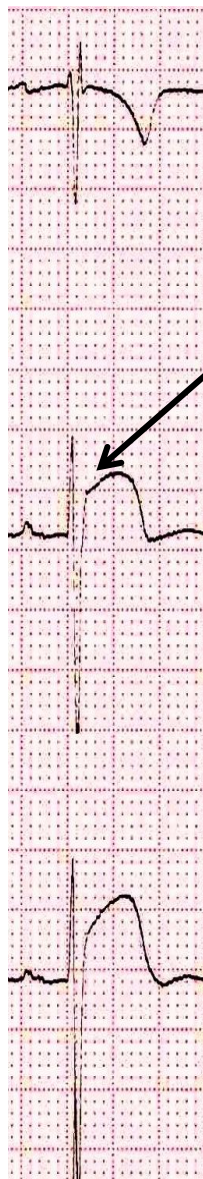
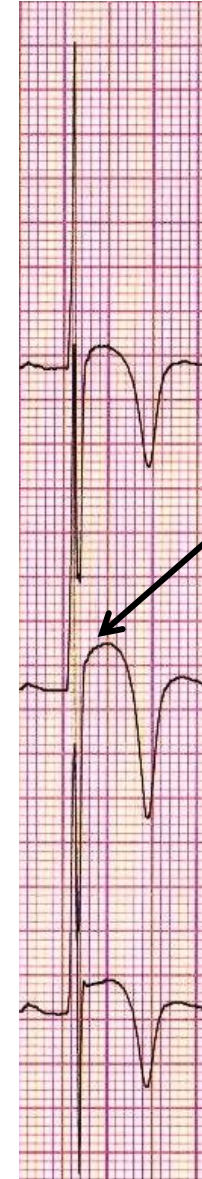
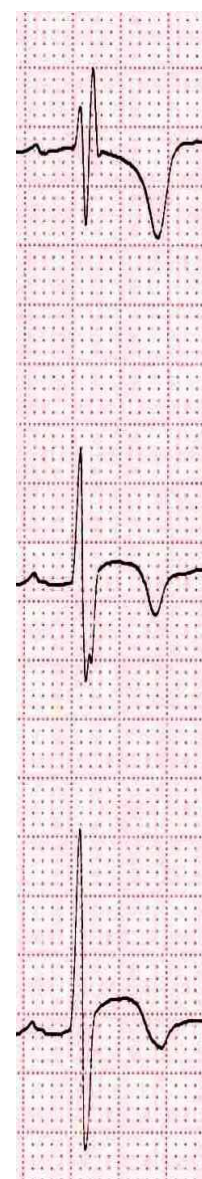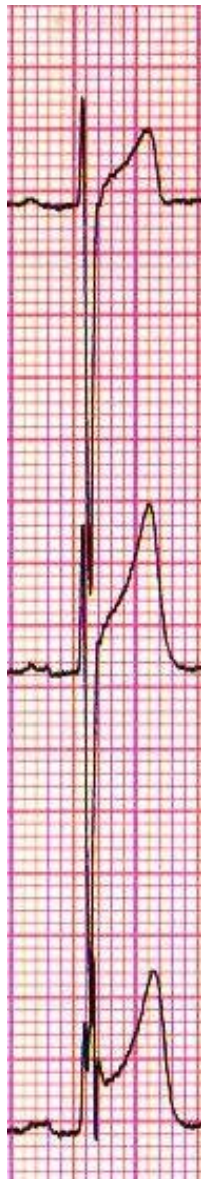
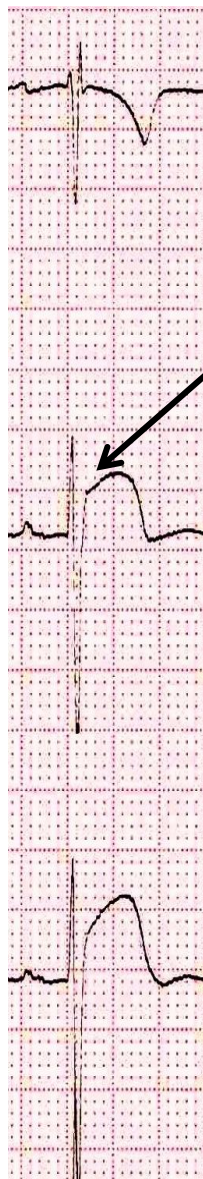
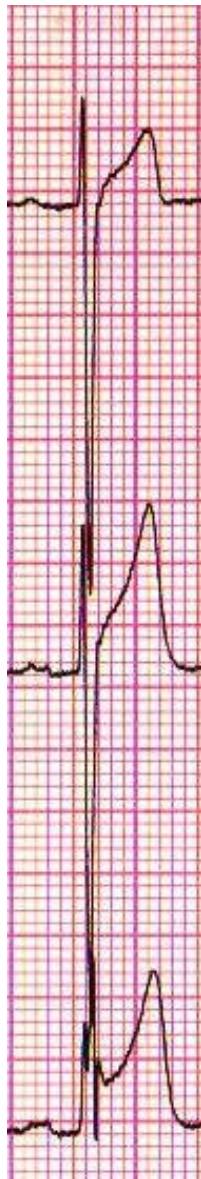
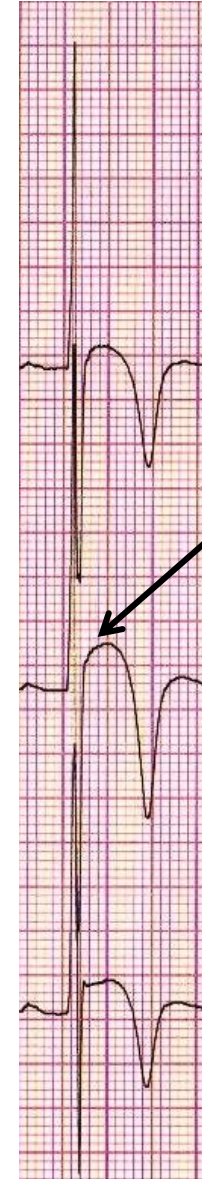
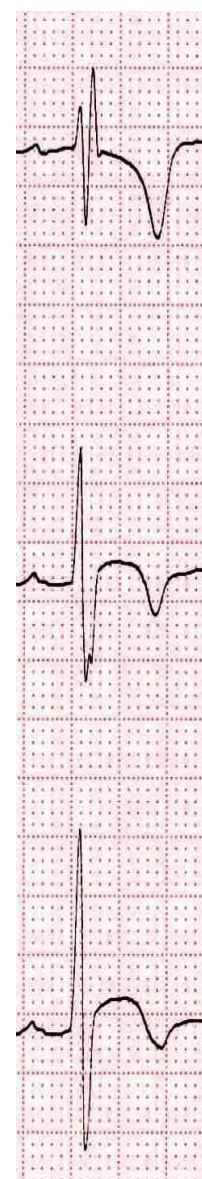
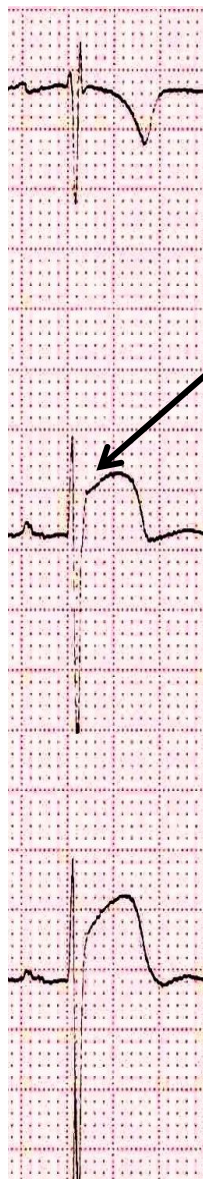


Anterior Precordial ECG Changes in Black Athletes

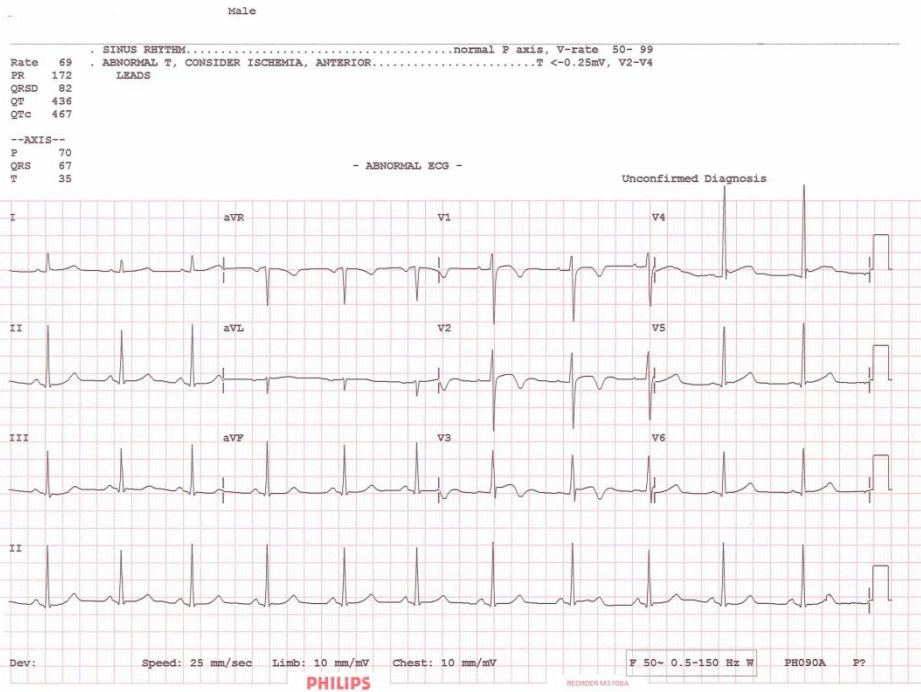
V1

V2

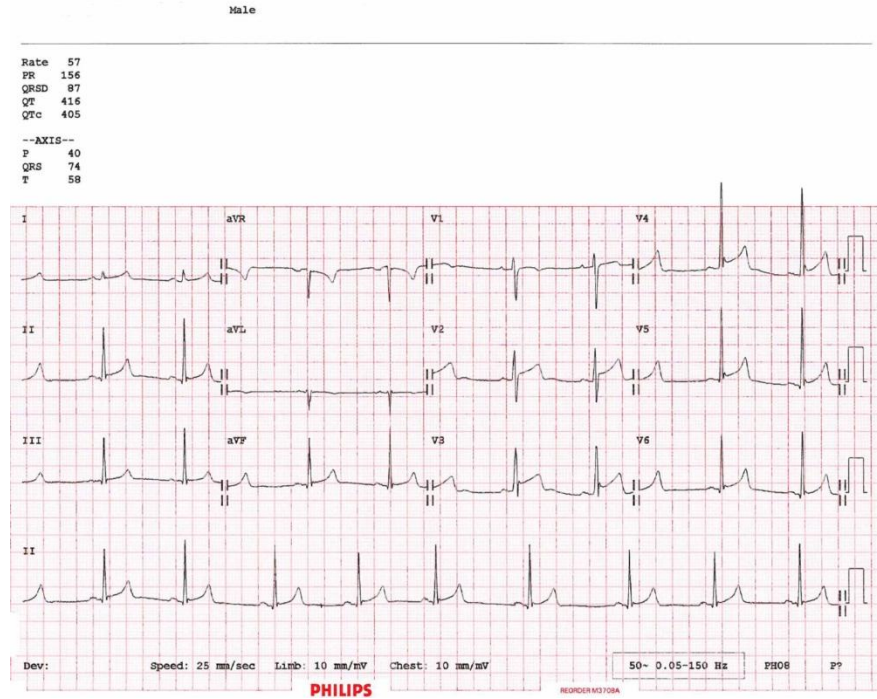
V3



Impact of Detraining on Repolarisation Changes



During peak season

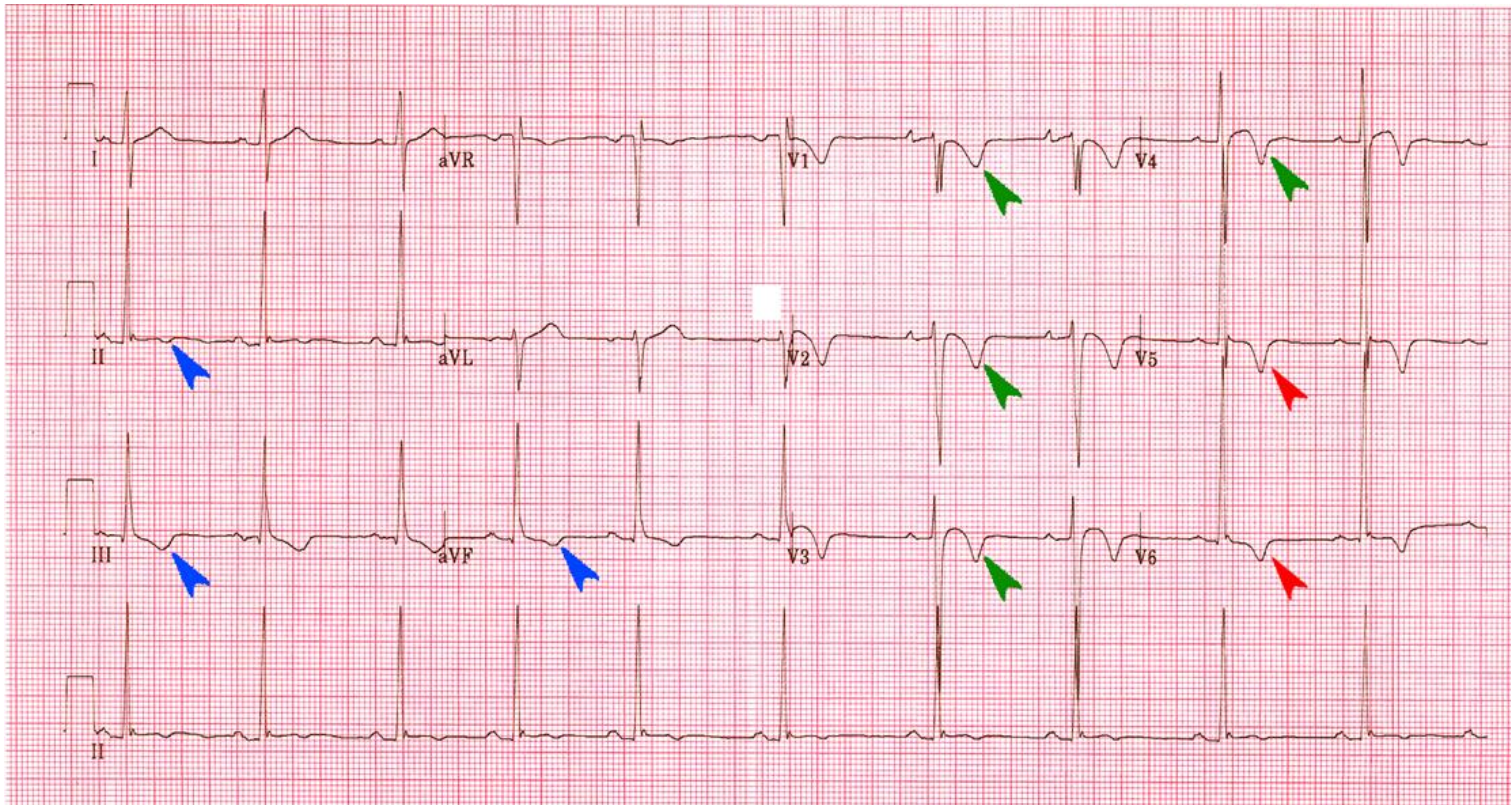


Off season

Message 4

T wave inversions in leads V1-V4 are present in 12-13% of black athletes are usually preceded by convex ST segment elevation.

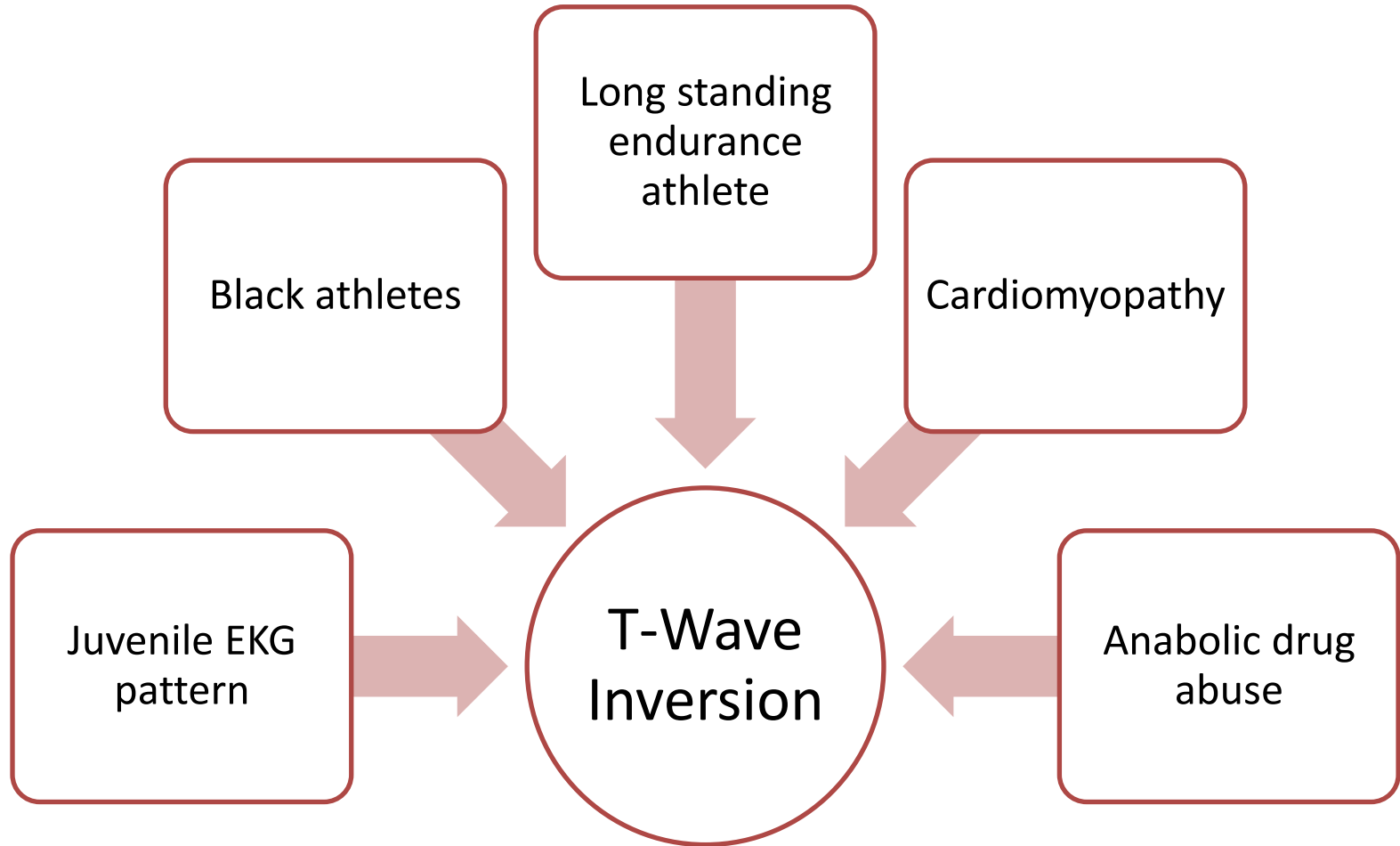
EKG from an asymptomatic black athlete.
Echocardiography was normal. Are any further investigations required?



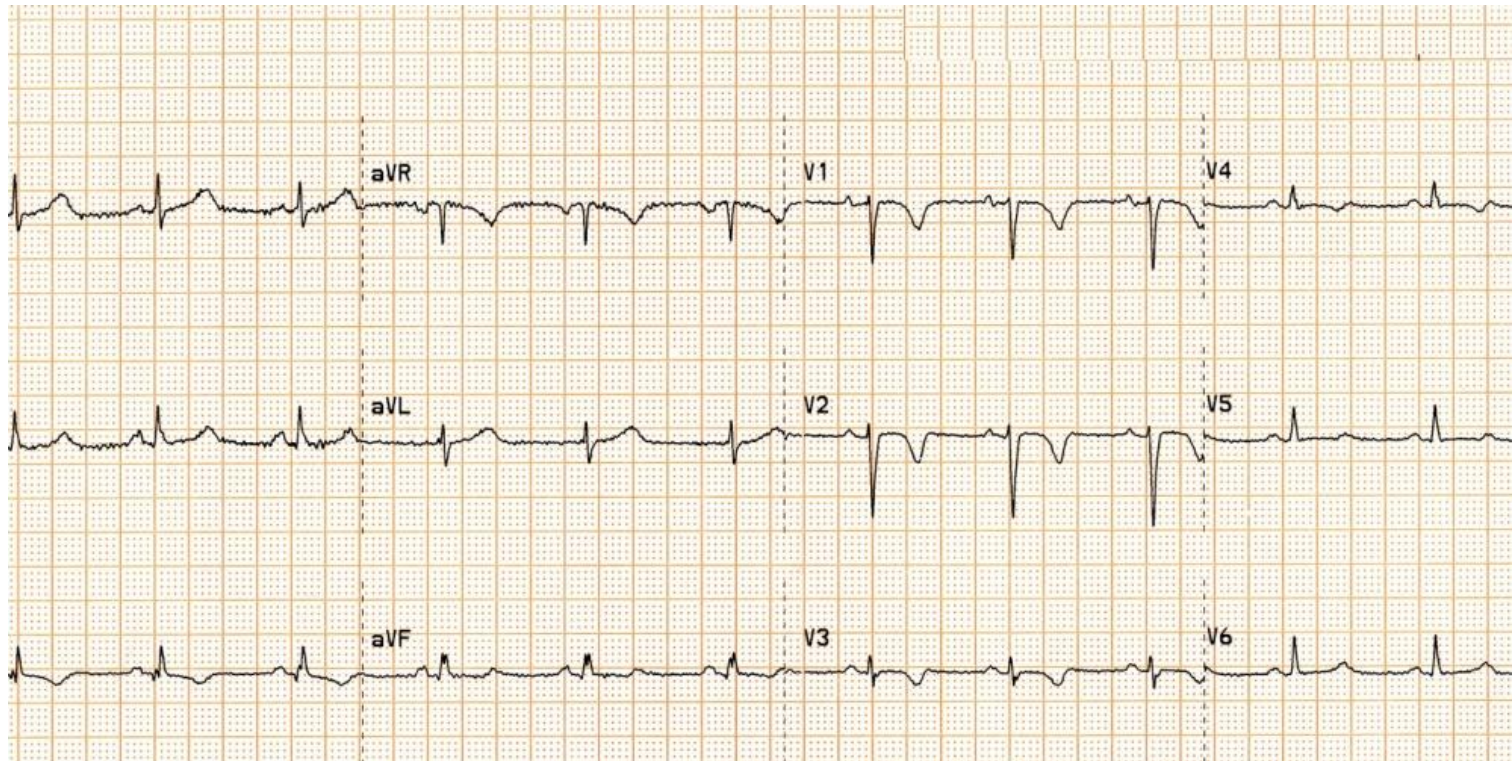
Message 5

T wave inversion in contiguous inferior leads or lateral leads warrant investigation in all athletes.

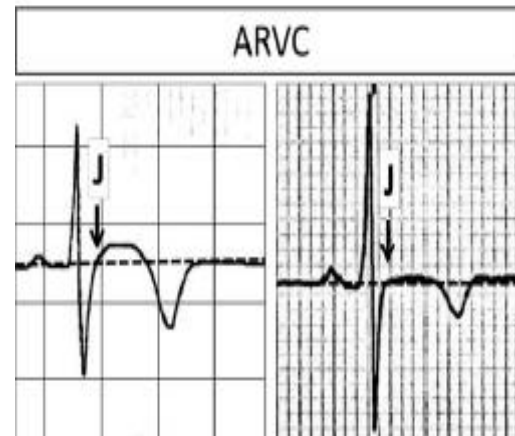
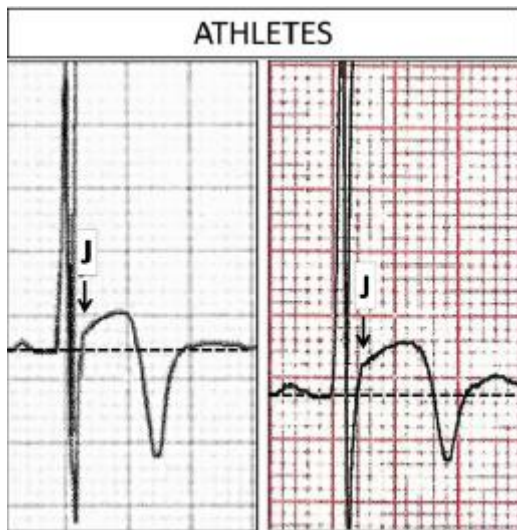
Interpretation of T Wave Inversion in Athletes



This is the ECG of a 21 year old white asymptomatic athlete. Is this normal?

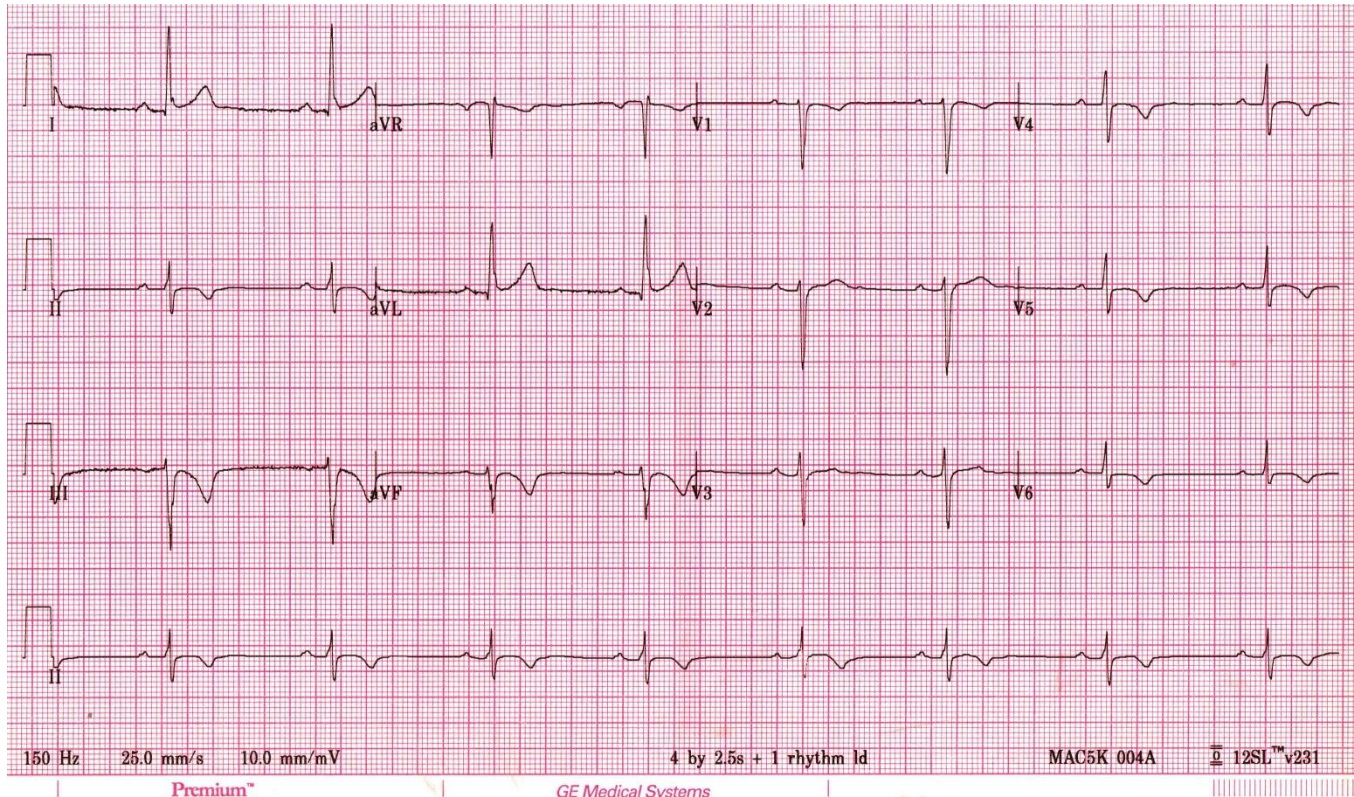


Electrocardiographic anterior T-wave inversion in athletes of different ethnicities: differential diagnosis between athlete's heart and cardiomyopathy

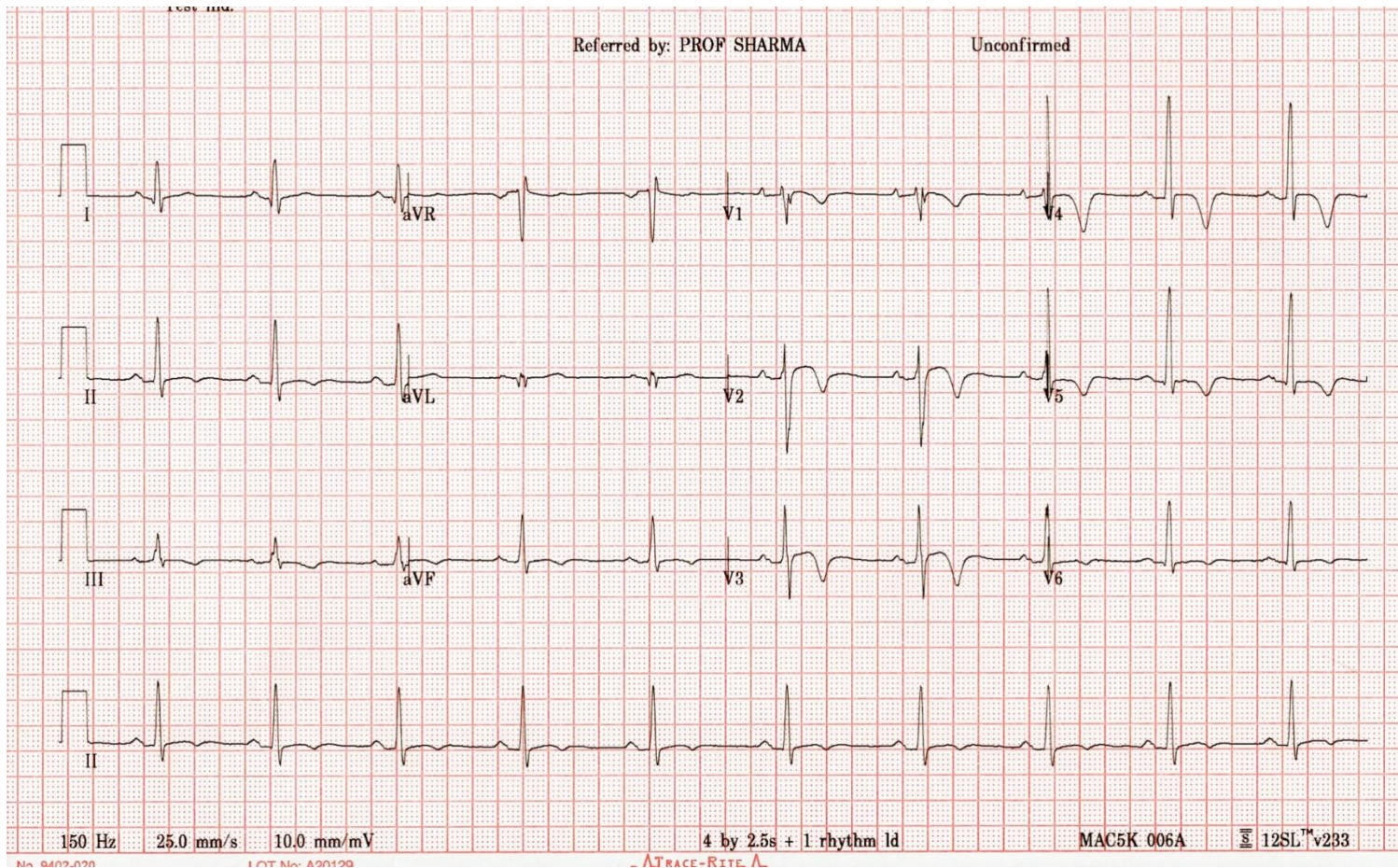


Calore et al. EHJ. 2015;

Athlete with ARVC



EKG in a Caucasian athlete. Normal or abnormal?

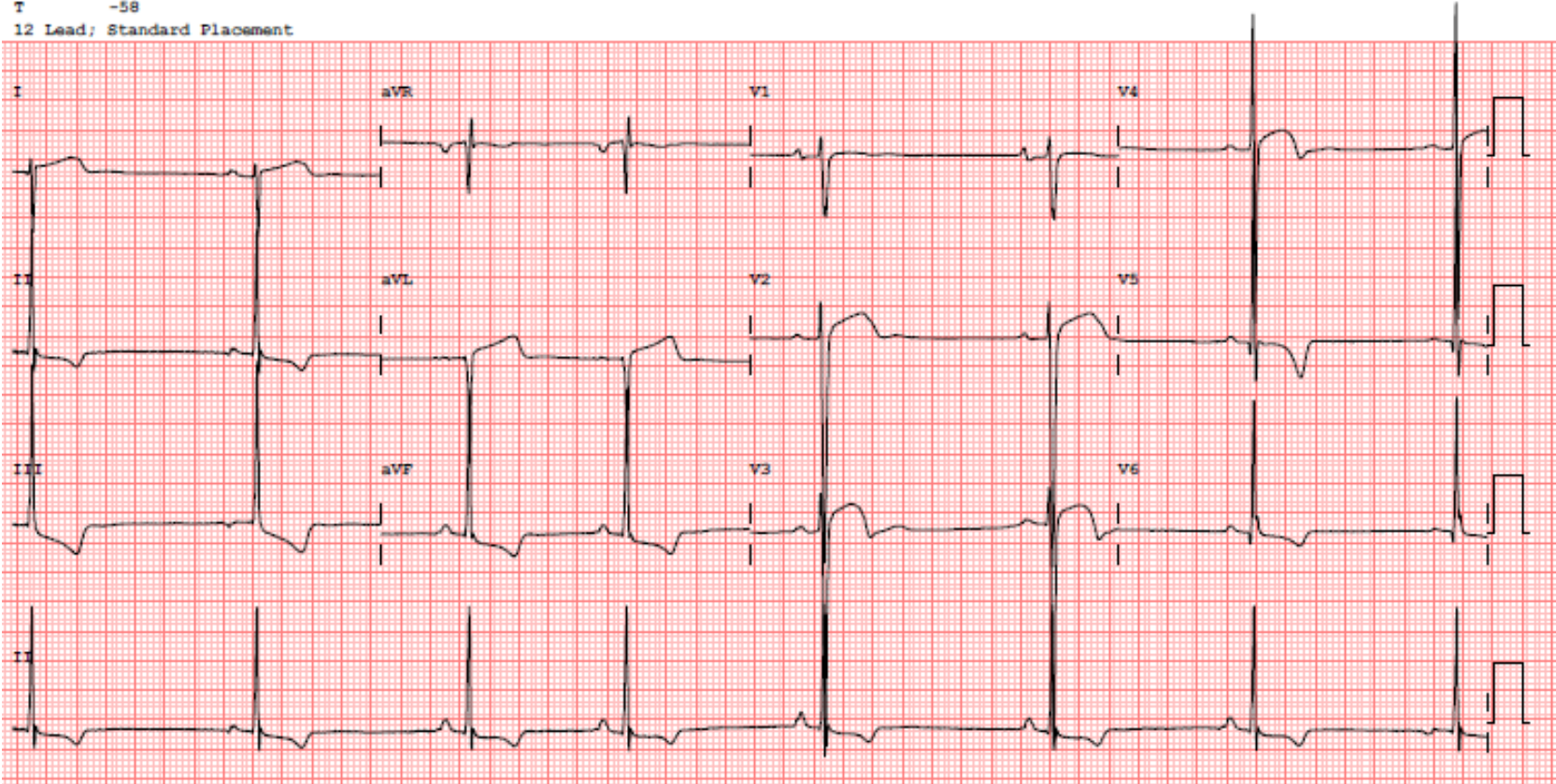


Inferolateral TWI with downsloping ST segments in II, III, aVf and V6

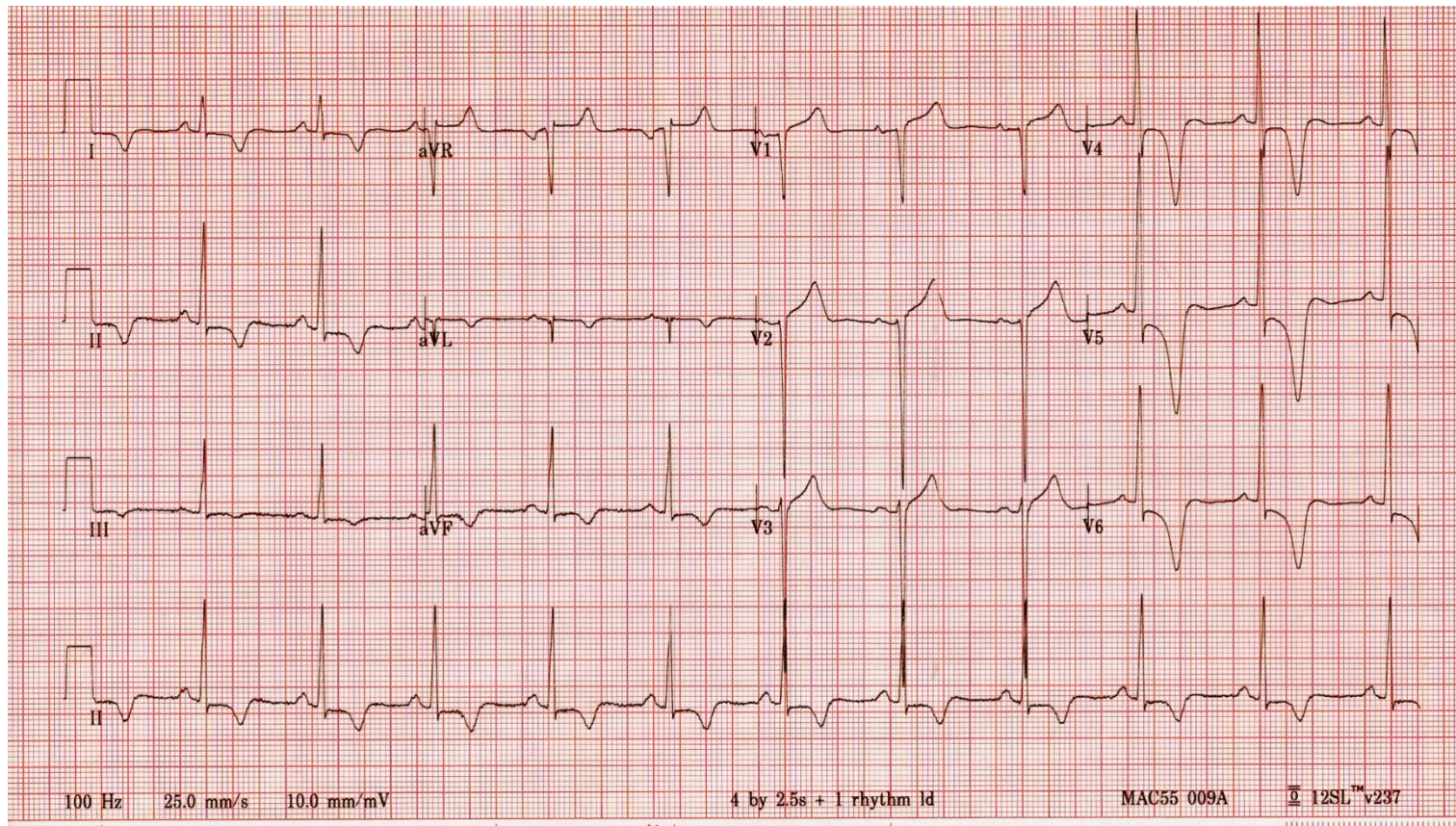
--AXIS--

P 52
QRS 107
T -58

12 Lead; Standard Placement



This is the ECG of a 24 year old asymptomatic black basket ball player. Echocardiography reported as normal. Are any further investigations required at this time?



Message 6

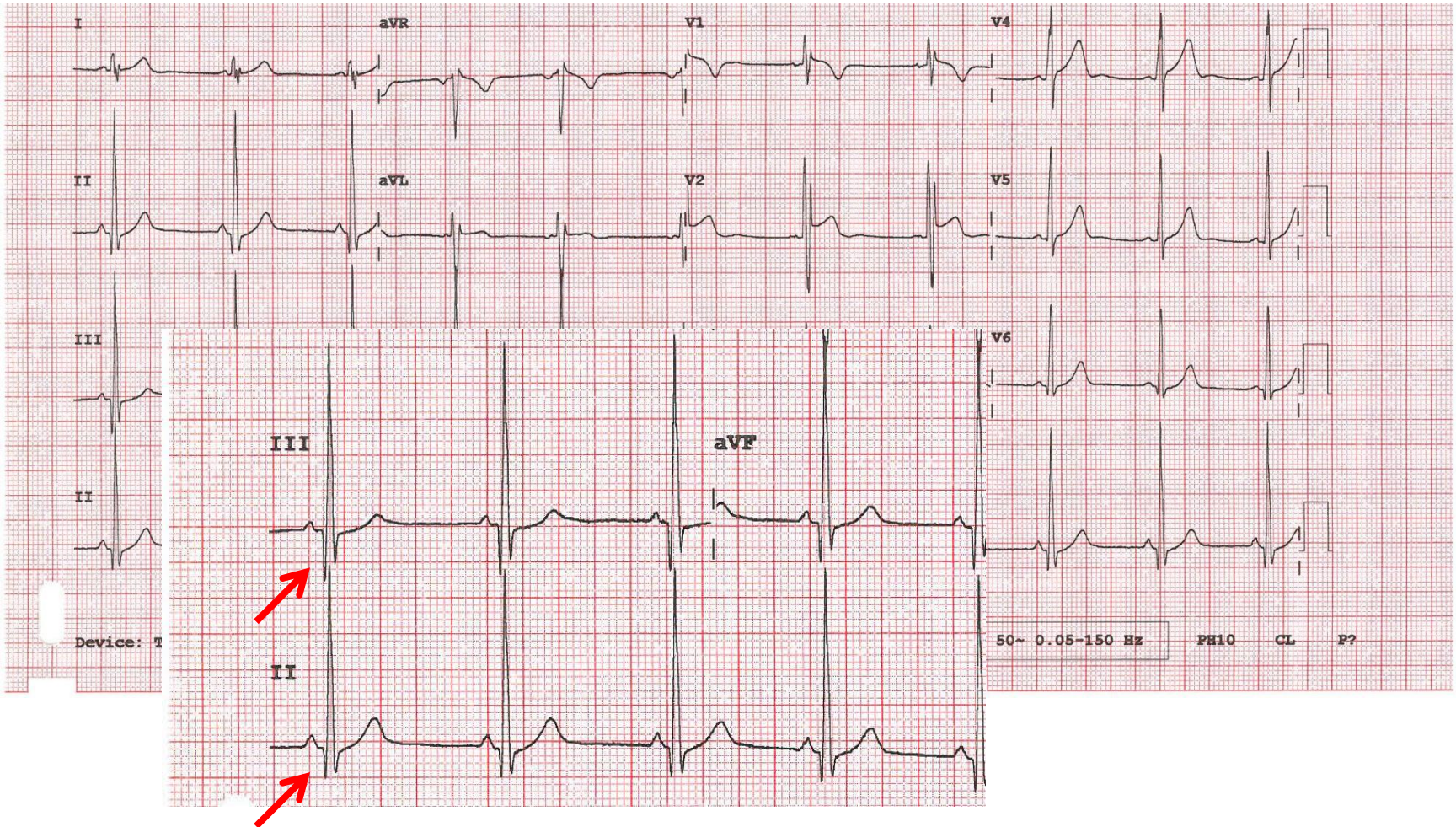
T wave inversion preceded by ST segment depression is suggestive of underlying pathology.

ST segment depression should always be considered abnormal.

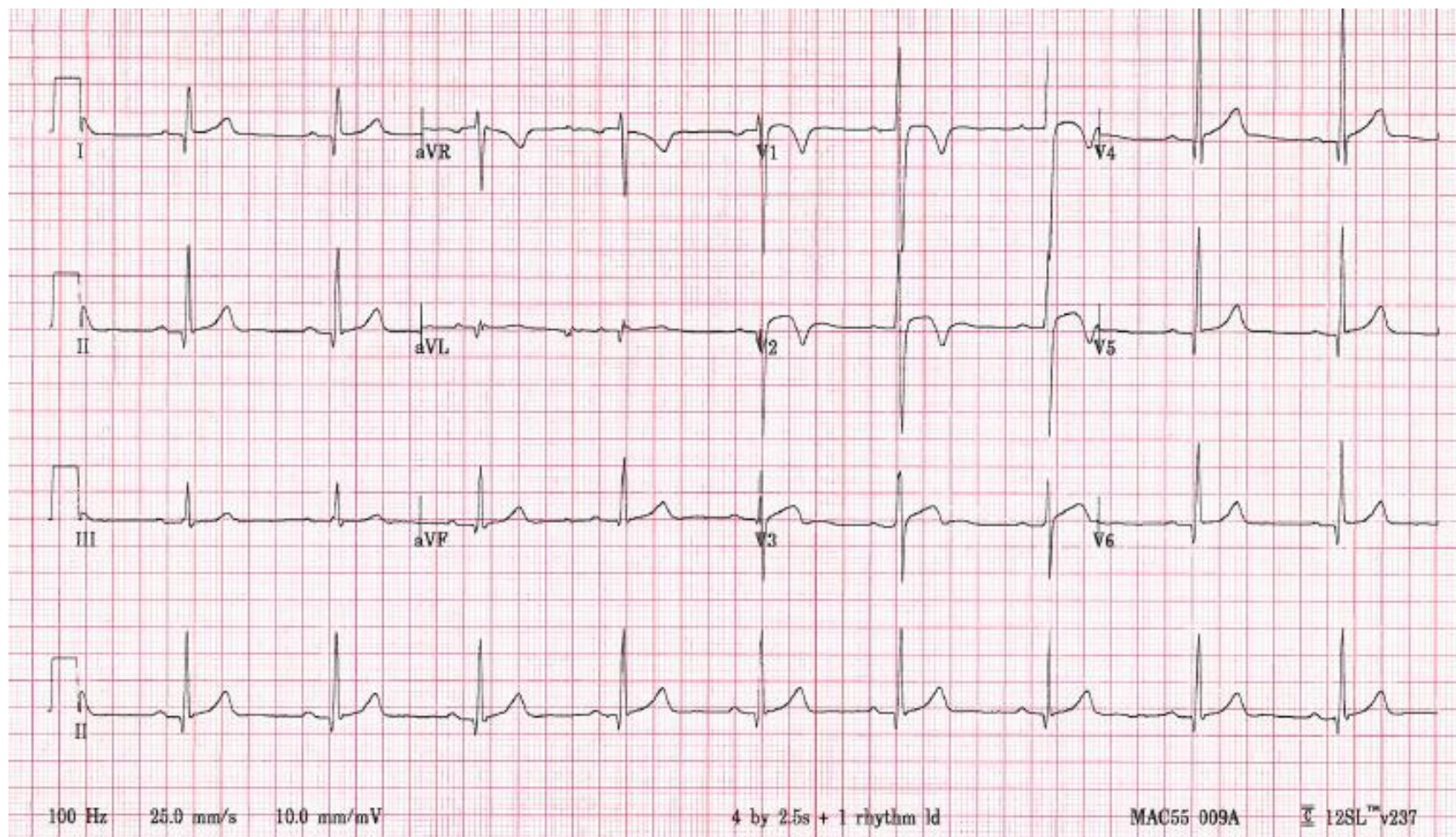
(Group 2)
Uncommon (< 5%)

- T-wave inversion
- ST-segment depression
- Pathological Q waves
- Left atrial enlargement
- Left axis deviation/left anterior hemiblock
- Right axis deviation/left posterior hemiblock
- Right ventricular hypertrophy
- Complete LBBB or RBBB
- Long or short QT interval
- Brugada-like early repolarization
- Ventricular arrhythmias

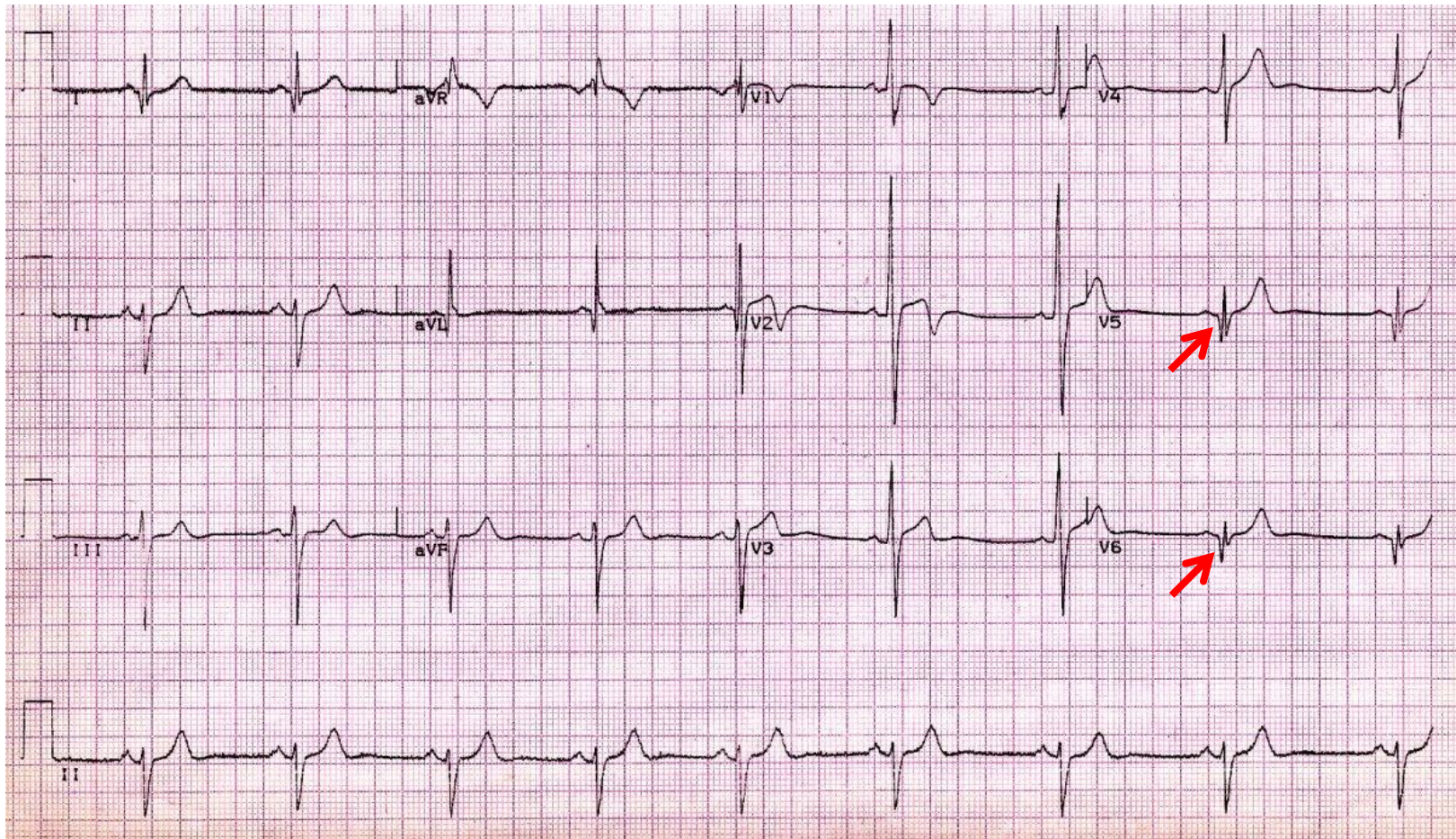
What is a Pathological Q Wave?



Pathological Q Waves in I, aVI, V5,V6



Pathological Q Waves



Message 7

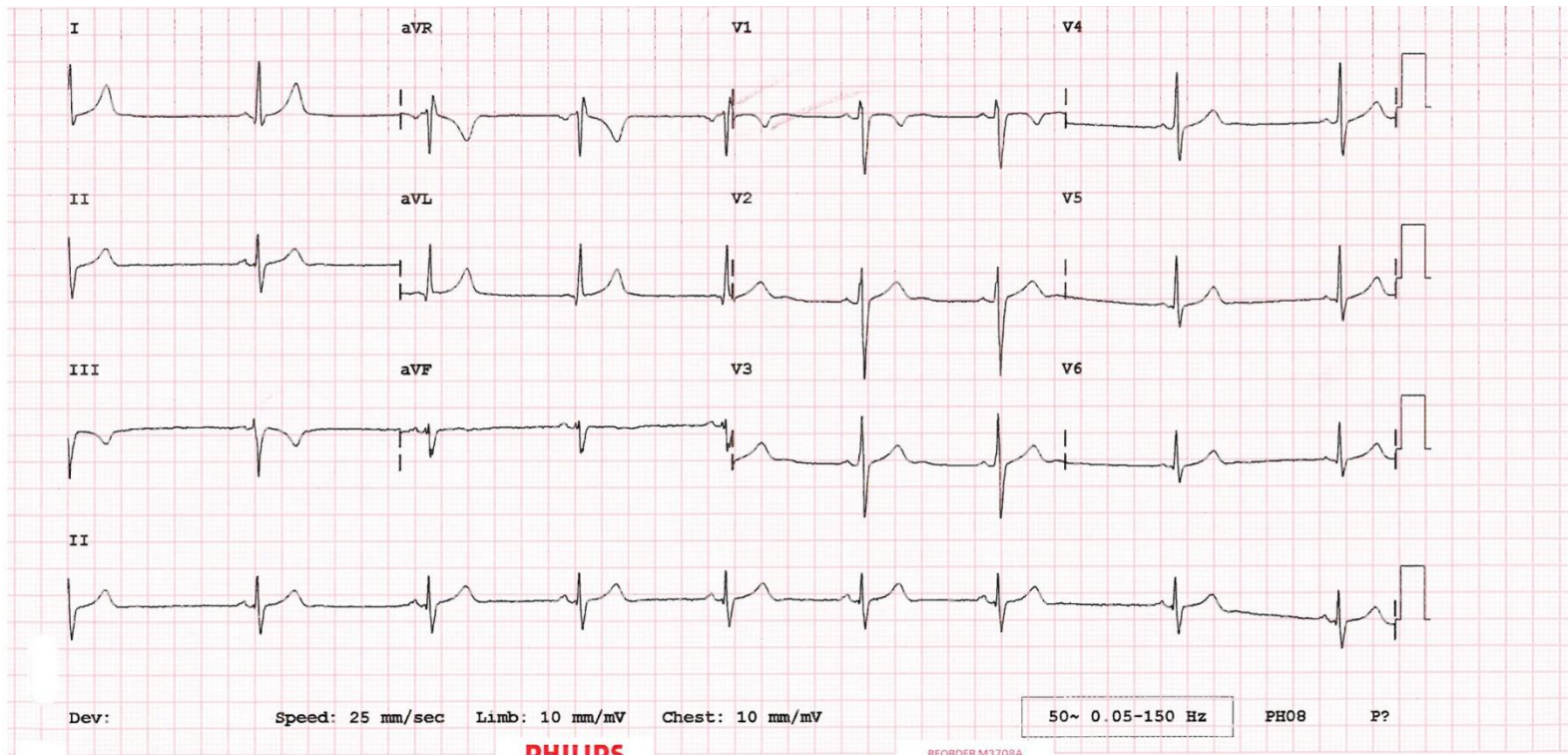
A pathological q wave (depth exceeds 25% of the height of the preceding R wave) is abnormal.

(Group 2)
Uncommon (< 5%)

- T-wave inversion
- ST-segment depression
- Pathological Q waves
- Left atrial enlargement
- Left axis deviation/left anterior hemiblock
- Right axis deviation/left posterior hemiblock
- Right ventricular hypertrophy
- Complete LBBB or RBBB
- Long or short QT interval
- Brugada-like early repolarization
- Ventricular arrhythmias

**53% of all Group
2 anomalies**

Left axis deviation



Left Atrial Enlargement

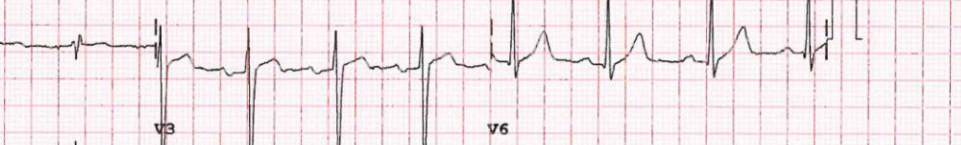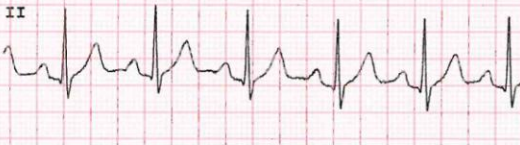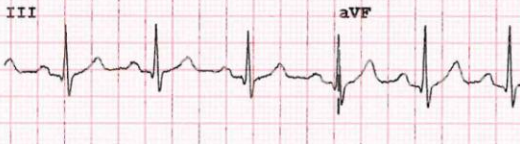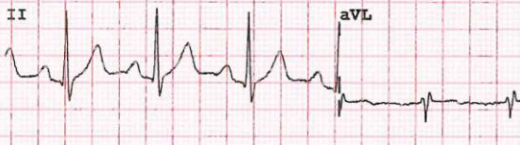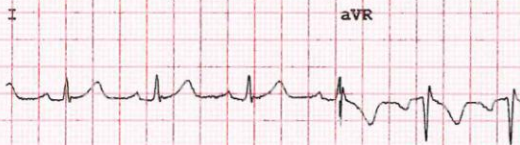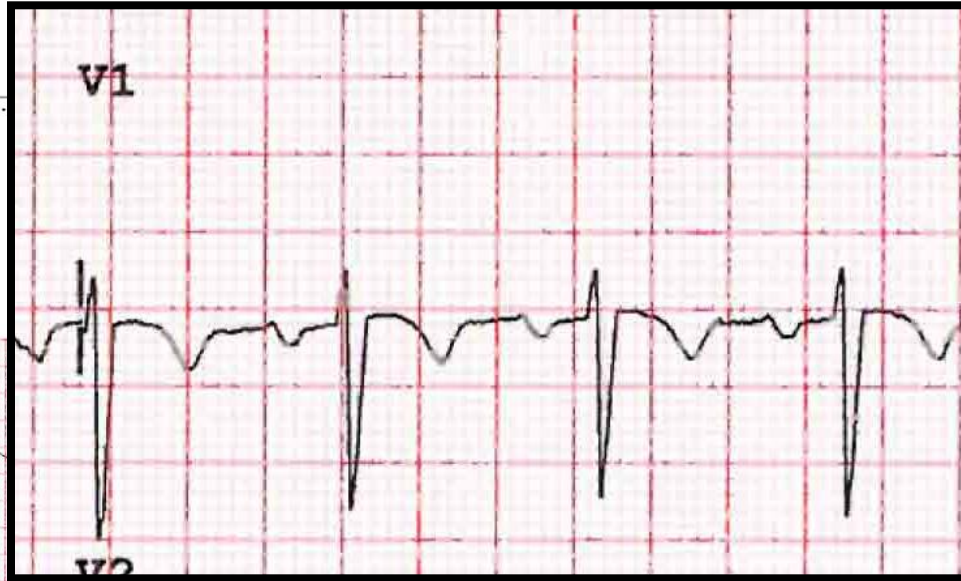5/01/2013 11:04:21
Female

Born

SINUS RHYTHM

Rate 90
PR 188
QRSD 94
QT 376
QTc 460

--AXIS--
P 67
QRS 47
T 54



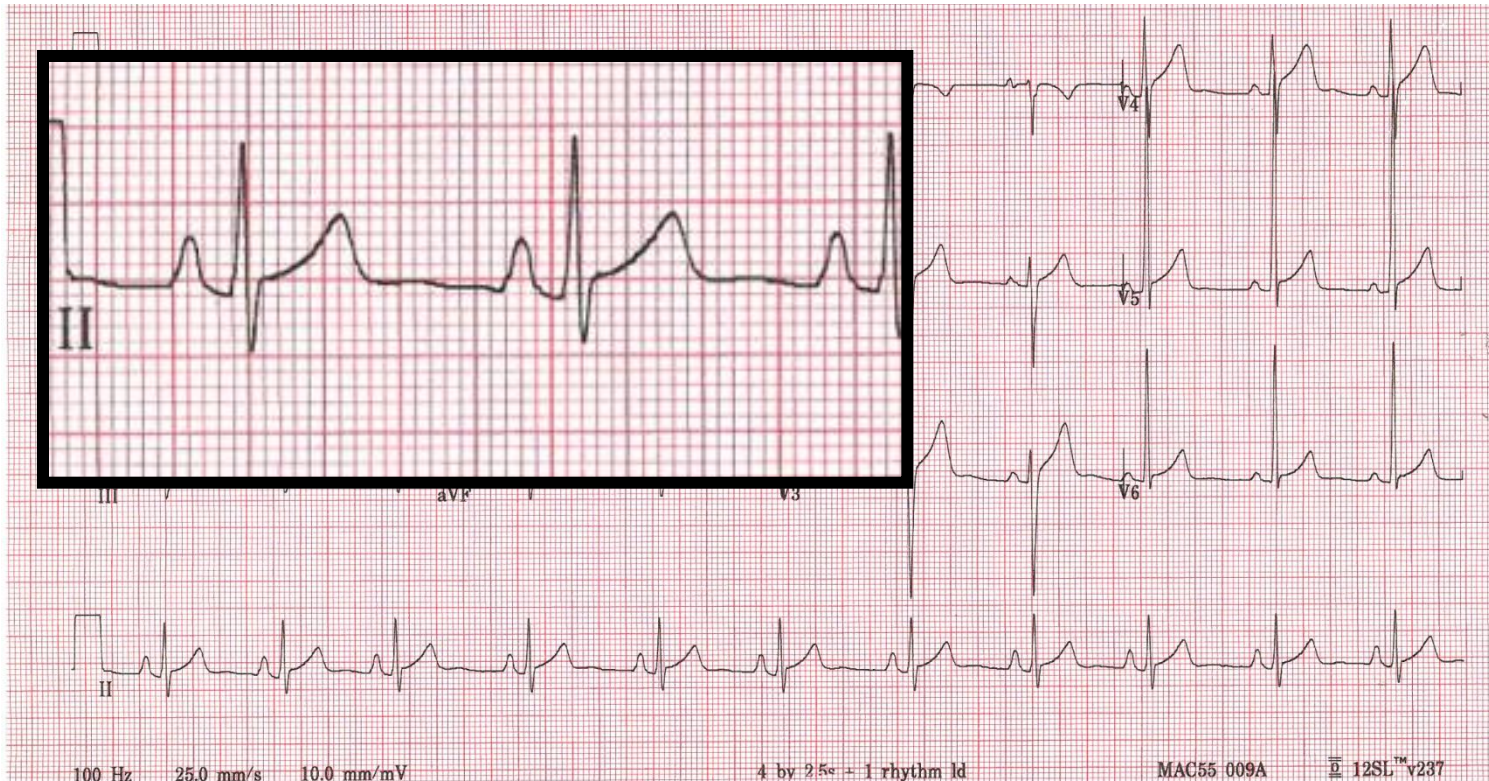
Dev: Speed: 25 mm/sec Limb: 10 mm/mV Chest: 10 mm/mV

50~ 0.05-150 Hz PH090A P?

PHILIPS

REORDER M3708A

Isolated voltage criterion for right atrial enlargement



Should axis deviation or atrial enlargement be categorised as abnormal in young athletes?

The athlete's electrocardiogram: time for re-appraisal of markers of pathology

2533 athletes and 9997 non athletes (14-35 years old)

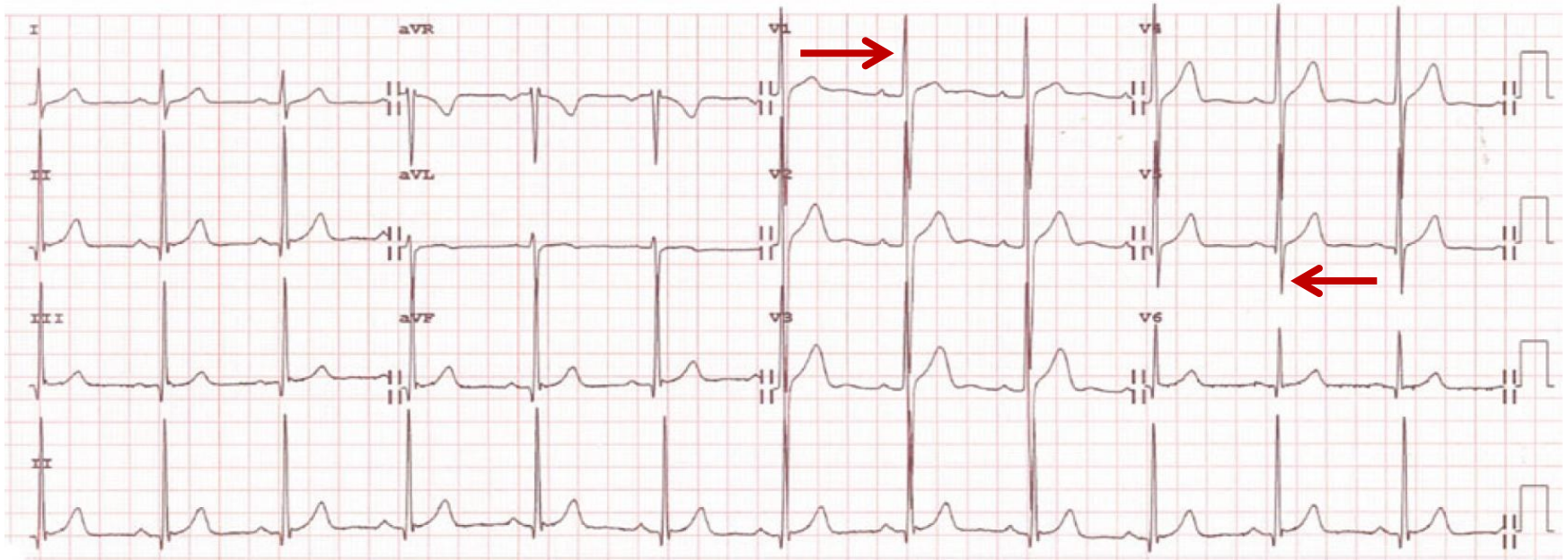
Axis deviation or atrial enlargement in isolation comprised 42.6% of all Group 2 changes in athletes.

These anomalies were more common in athletes (5.5% vs 4.4%)

579 individuals with these anomalies were tested and none showed sinister cardiac disease.

Exclusion resulted in a sensitivity of 89.5% and a specificity of 94%

Sokolow-Lyon Voltage Criteria for RVH



Sum of R in V1 + S in V5 (or V6) ≥ 10 mm

Clinical significance of electrocardiographic right ventricular hypertrophy in athletes: comparison with arrhythmogenic right ventricular cardiomyopathy and pulmonary hypertension

627 athletes and 241 controls

RVH criteria in 11.8% (1 in 8) athletes and 6.2% controls

RVH plus RAD present in 8.1% athletes and 0.2% of controls

None revealed right ventricular pathology

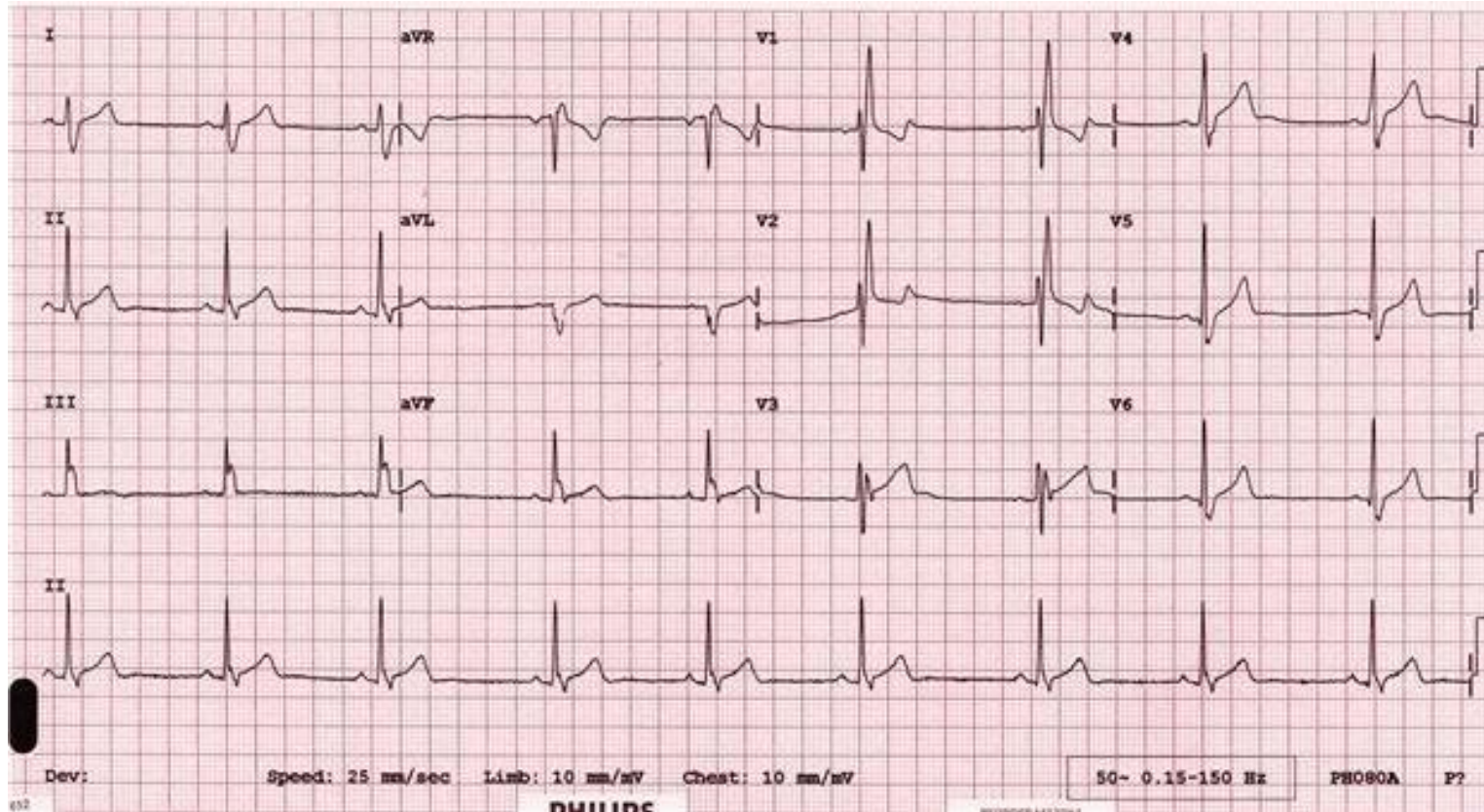
Message 8

The presence of any one of left axis deviation, right axis deviation, voltage criterion for left atrial enlargement, voltage criterion for right atrial enlargement and voltage criterion for right ventricular hypertrophy in isolation or with other Group 1 changes does not warrant investigation in asymptomatic athletes with normal physical examination.

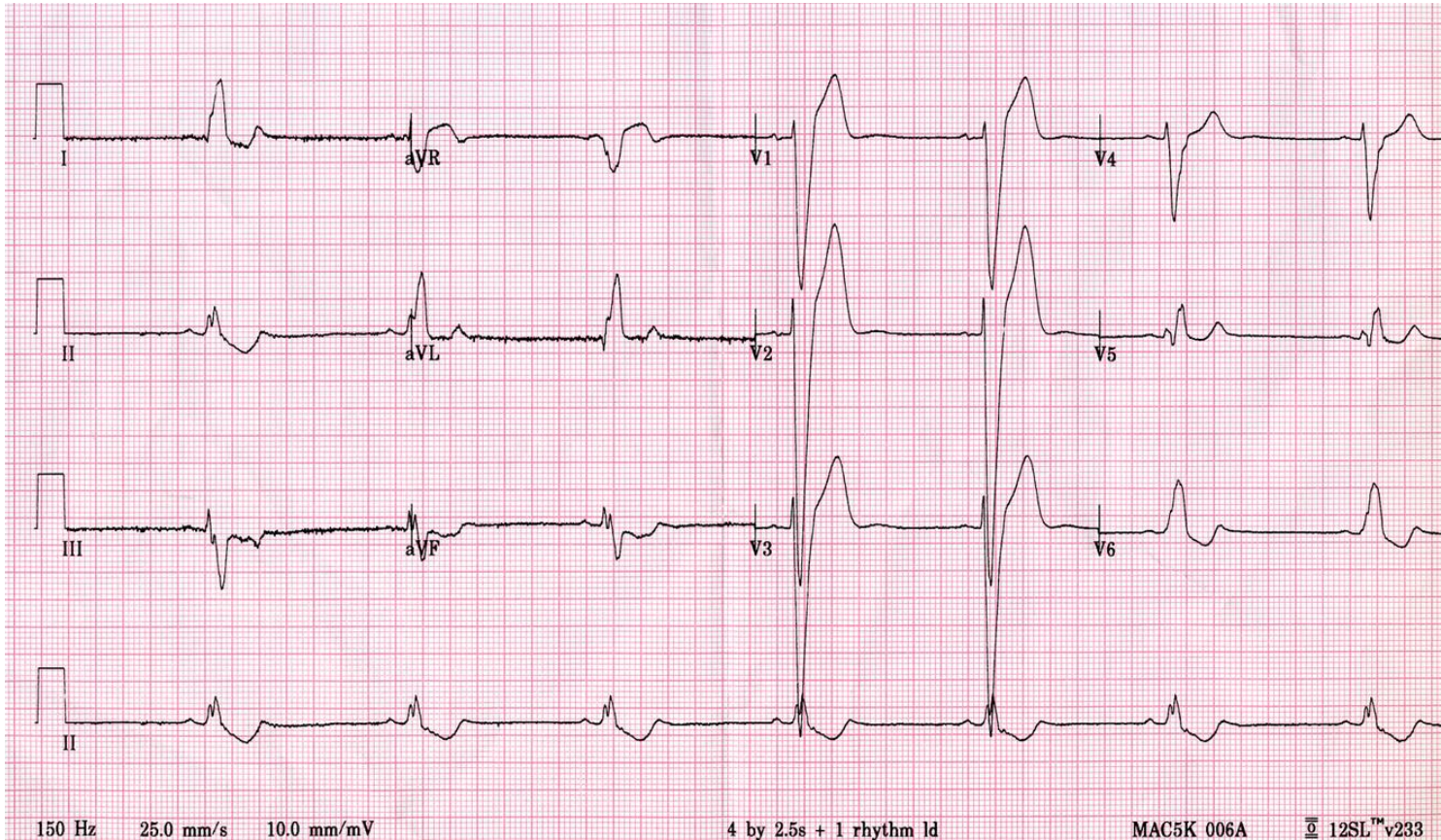
(Group 2)
Uncommon (< 5%)

- T-wave inversion
- ST-segment depression
- Pathological Q waves
- Left atrial enlargement
- Left axis deviation/left anterior hemiblock
- Right axis deviation/left posterior hemiblock
- Right ventricular hypertrophy
- Complete LBBB or RBBB
- Long or short QT interval
- Brugada-like early repolarization
- Ventricular arrhythmias

Complete Right Bundle Branch Block



30 year old cyclist had an routine EKG. Are further investigations required?



Message 9

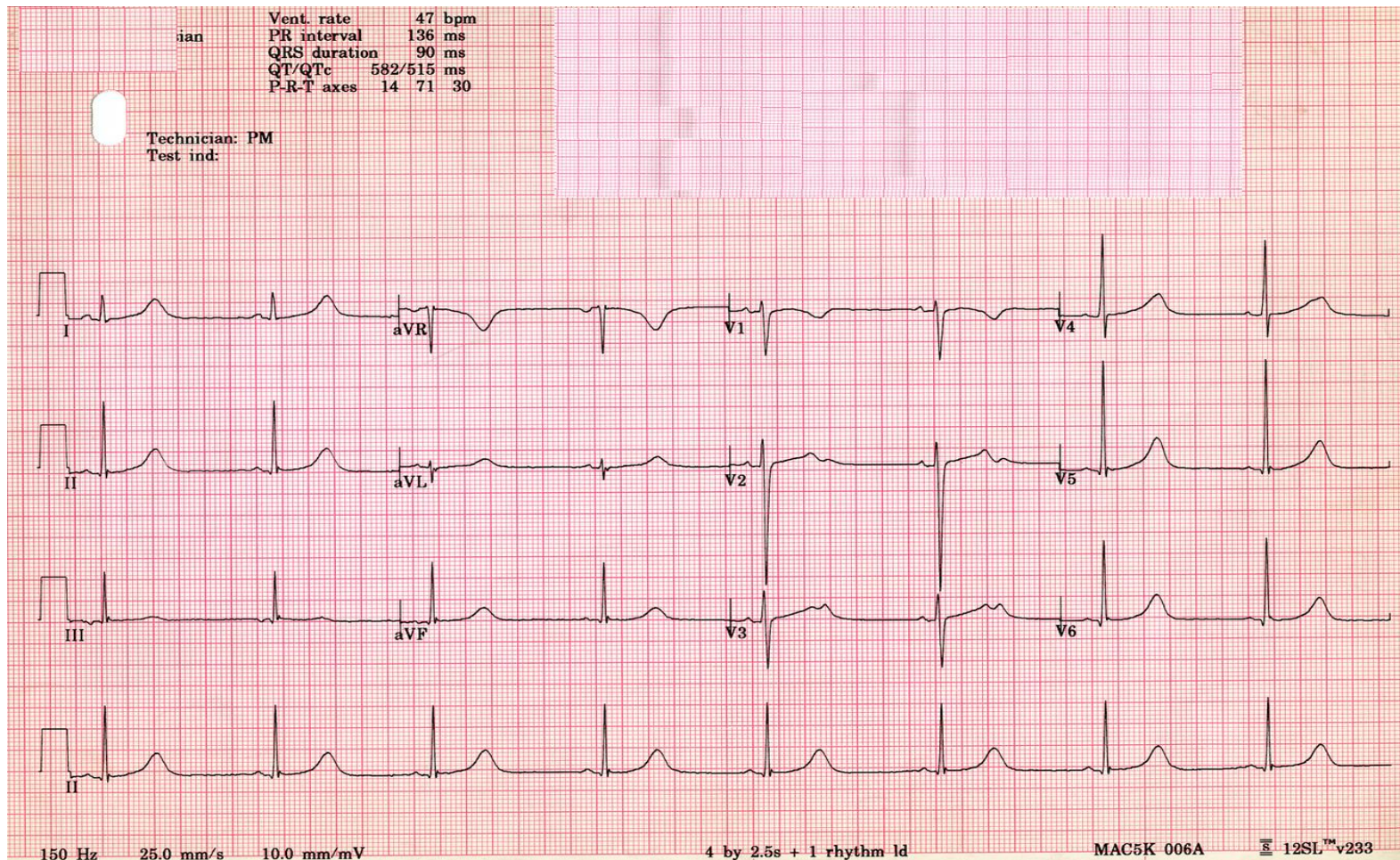
LBBB always warrants investigation.

The significance of RBBB is less clear but I would recommend echocardiography.

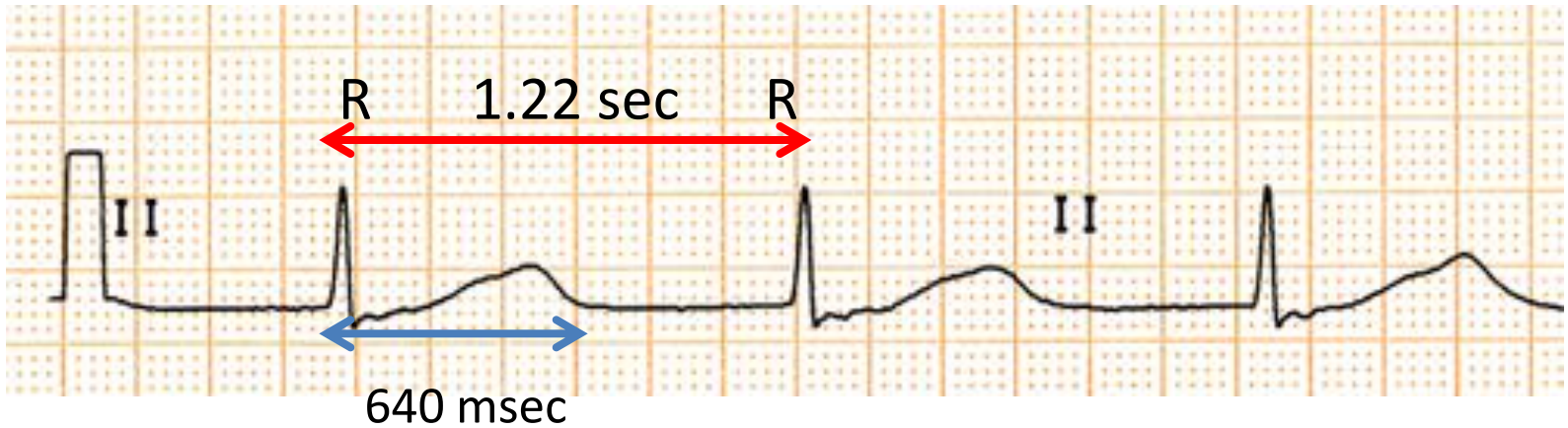
(Group 2)
Uncommon (< 5%)

- T-wave inversion
- ST-segment depression
- Pathological Q waves
- Left atrial enlargement
- Left axis deviation/left anterior hemiblock
- Right axis deviation/left posterior hemiblock
- Right ventricular hypertrophy
- Complete LBBB or RBBB
- Long or short QT interval
- Brugada-like early repolarization
- Ventricular arrhythmias

This 15 year old boy experienced a bout of dizziness and near collapse just before a game of football. What is the abnormality?



Calculation of the QT interval



$$QTc = QT/\sqrt{RRR}$$

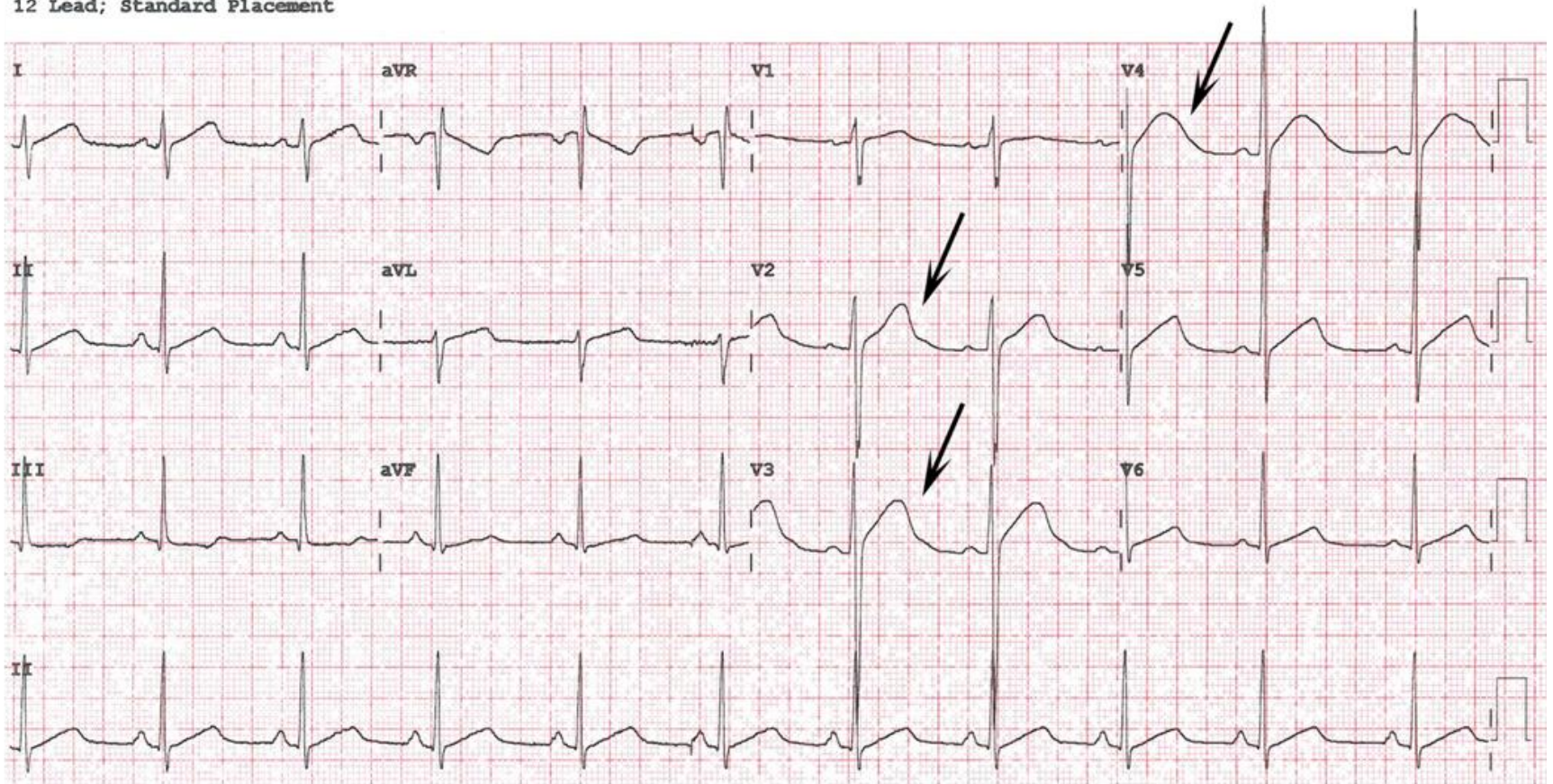
$$QTc = 640/\sqrt{1.22} = 584 \text{ msec}$$

Problems with Measuring QT Interval in Athletes

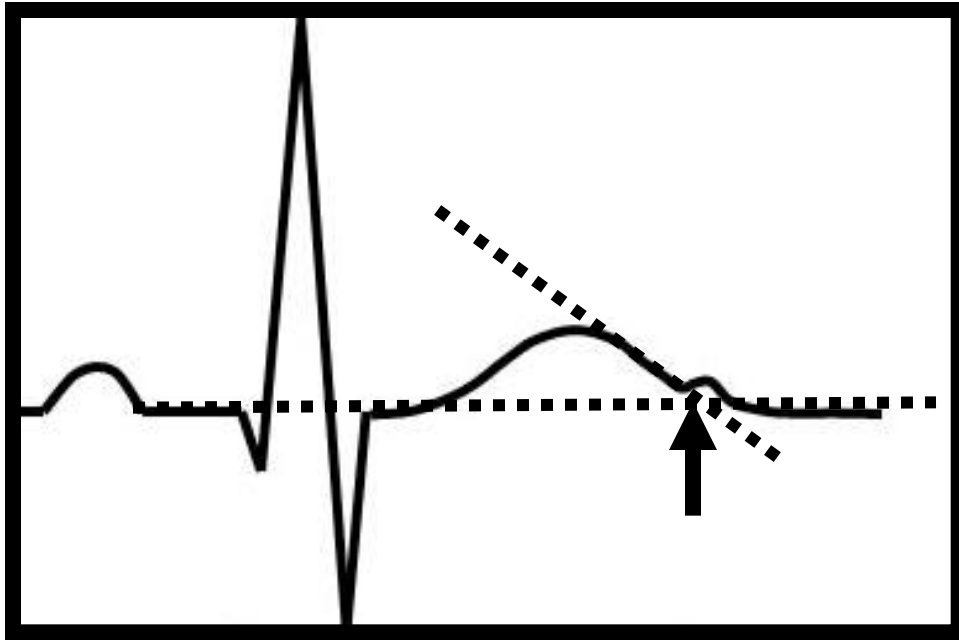
Slow HR	Prevalence of Long QT in general population
Sinus arrhythmia	1 in 2000
Slightly wide QRS complexes	Prevalence of Long QT in athletes is 1 in 125 to 1 in 250
T-U complexes	

Long QT or normal?

12 Lead; Standard Placement

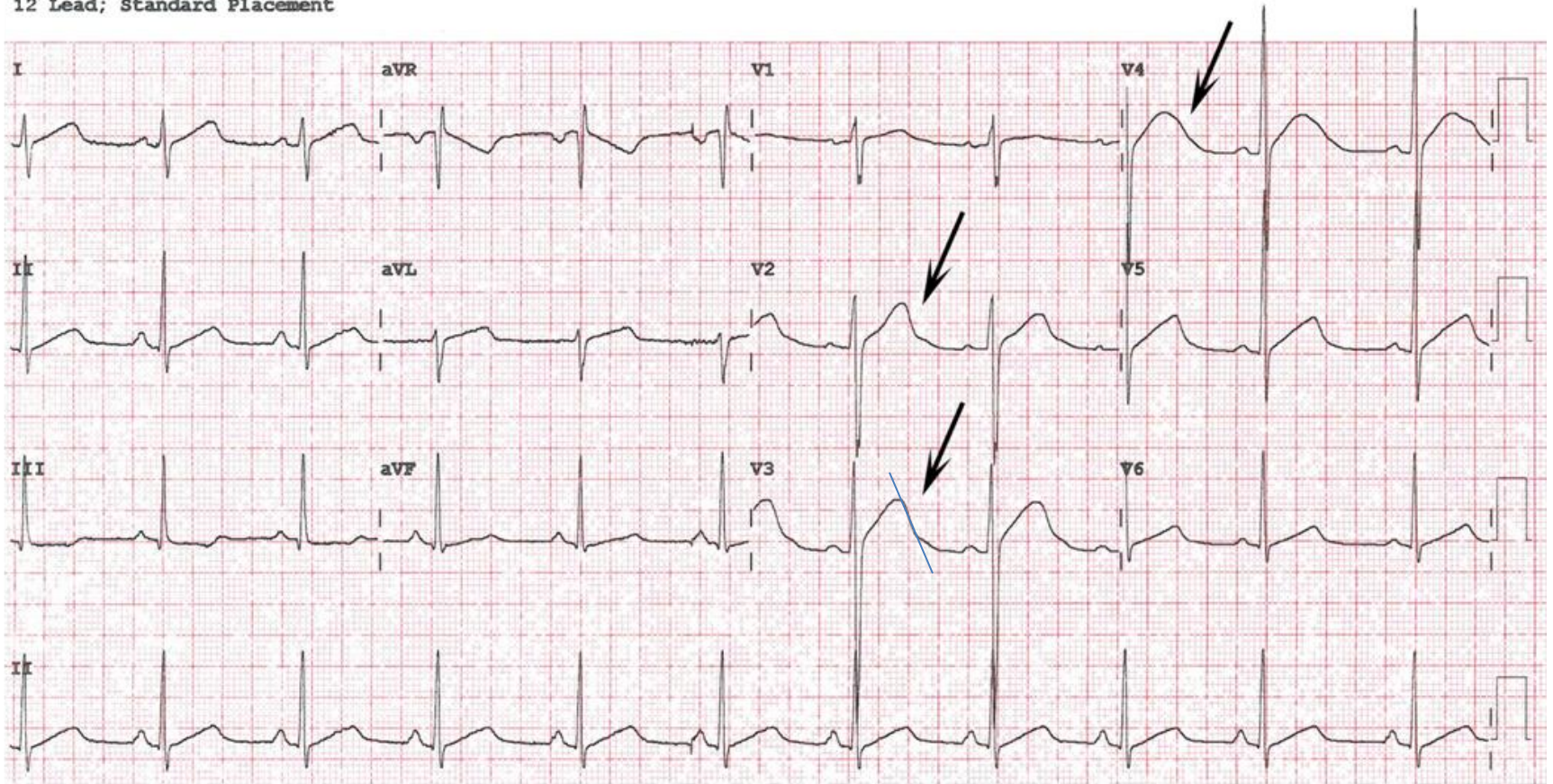


QT Interval Measurement



Prolonged QT interval

12 Lead; Standard Placement



(Group 2)
Uncommon (< 5%)

- T-wave inversion
- ST-segment depression
- Pathological Q waves
- Left atrial enlargement
- Left axis deviation/left anterior hemiblock
- Right axis deviation/left posterior hemiblock
- Right ventricular hypertrophy
- Complete LBBB or RBBB
- Long or short QT interval
- Brugada-like early repolarization
- Ventricular arrhythmias

6%

QT Interval Measurement

$$QTc = QT / \sqrt{RR}$$

ABNORMAL (ESC)

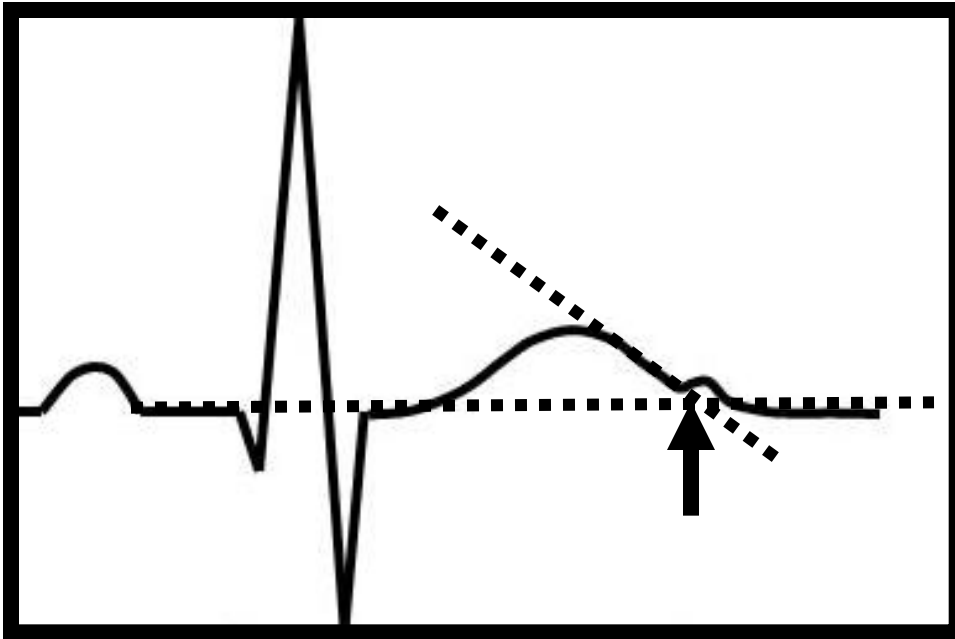
$QTc > 440$ in males

$QTc > 460$ in females

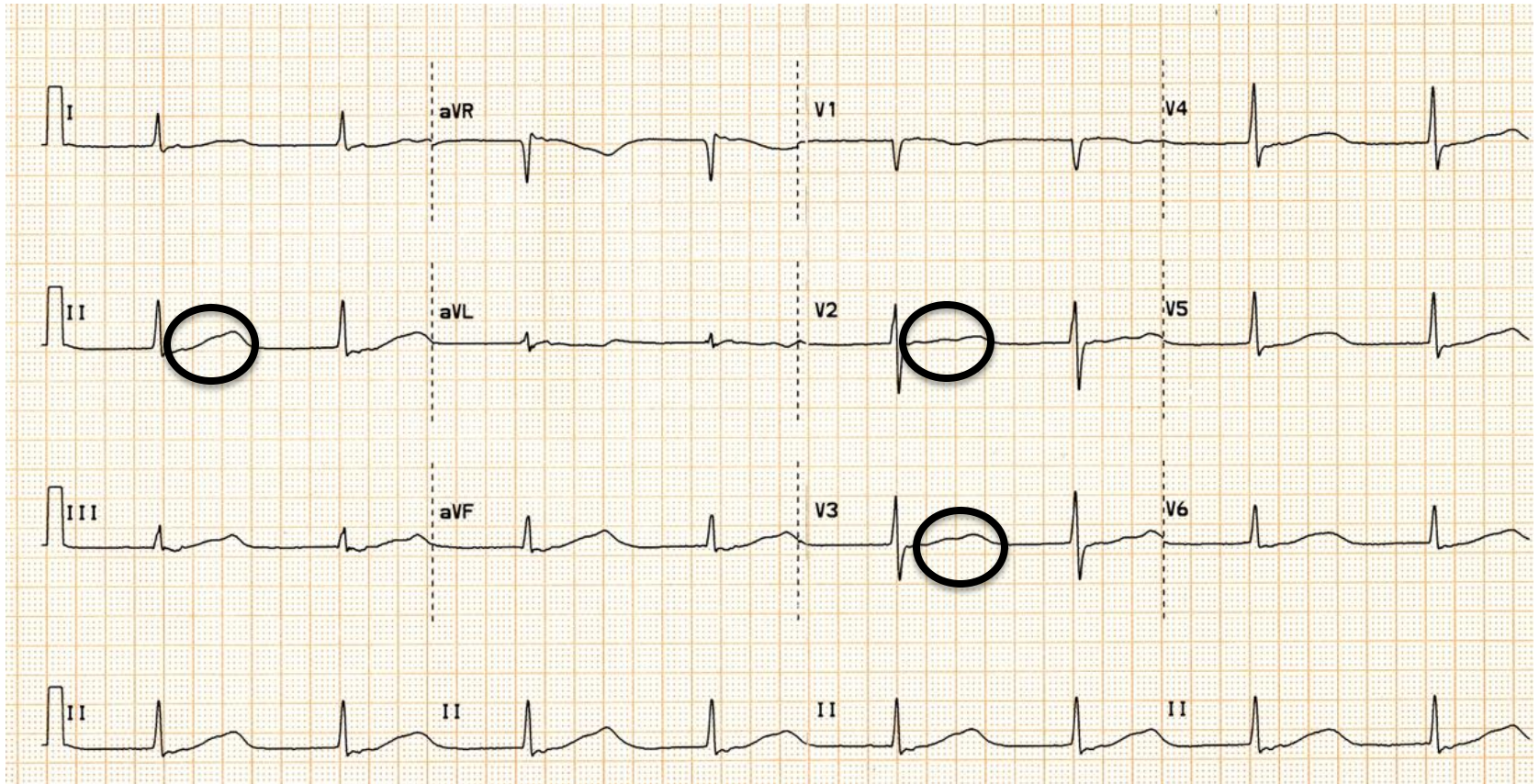
ABNORMAL (AHA)

$QTc > 470$ in males

$QTc > 480$ in females



Long QT interval



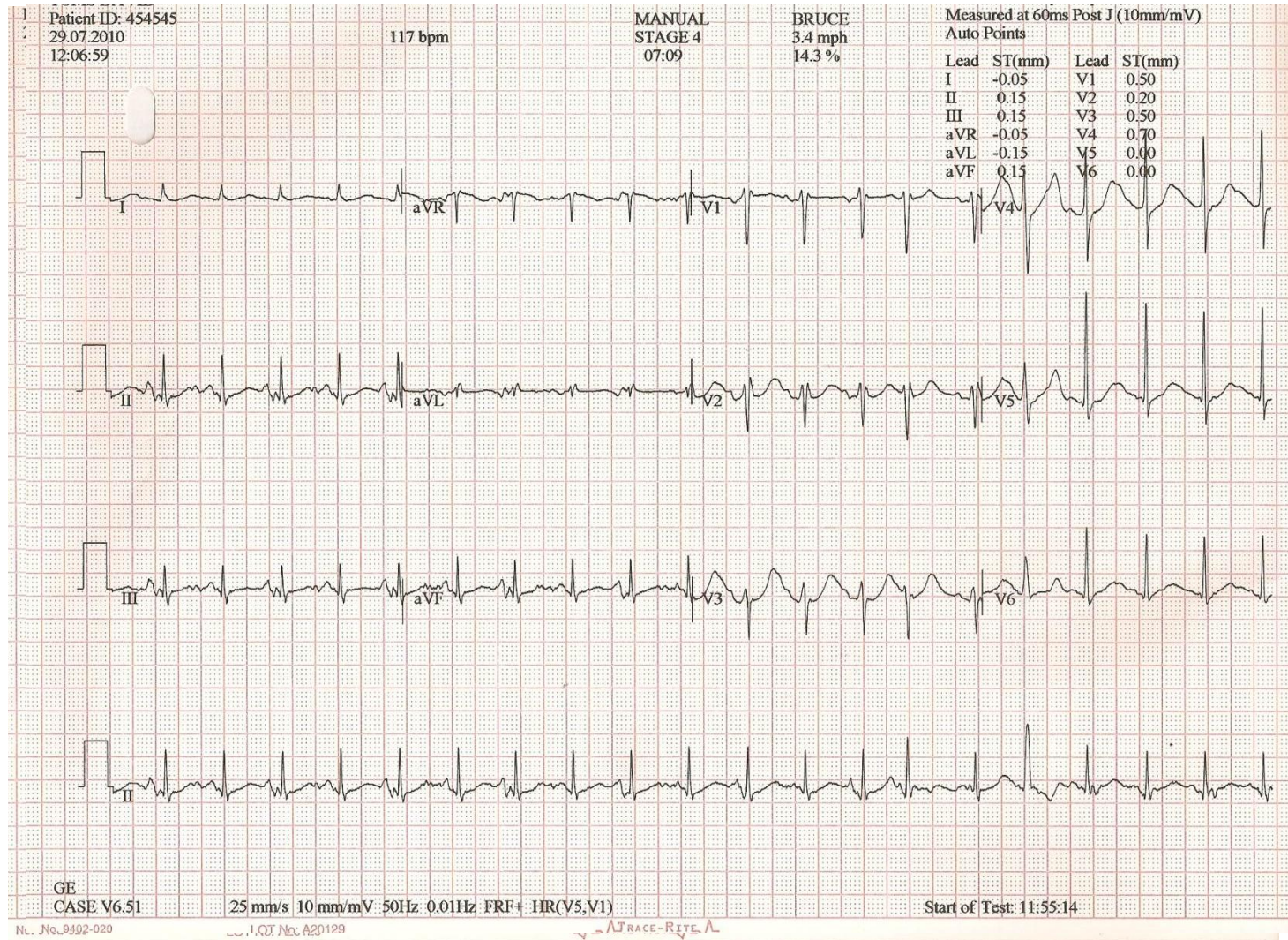
T wave notching

Diagnosis of LQTS in an athlete with QT interval 460-490 msec

Diagnosis based on a long QTc in the context of at least 1 of the following:

1. Unheralded Syncope
2. Torsades de pointes
3. Identification of a long QTc in first degree relatives
4. Family history of SADS
5. Notched T waves
6. Paradoxical QT prolongation with exercise

Paradoxical prolongation of the QT



Message 10

A QTc > 470 in males or > 480 in females is abnormal especially

If there is T wave notching

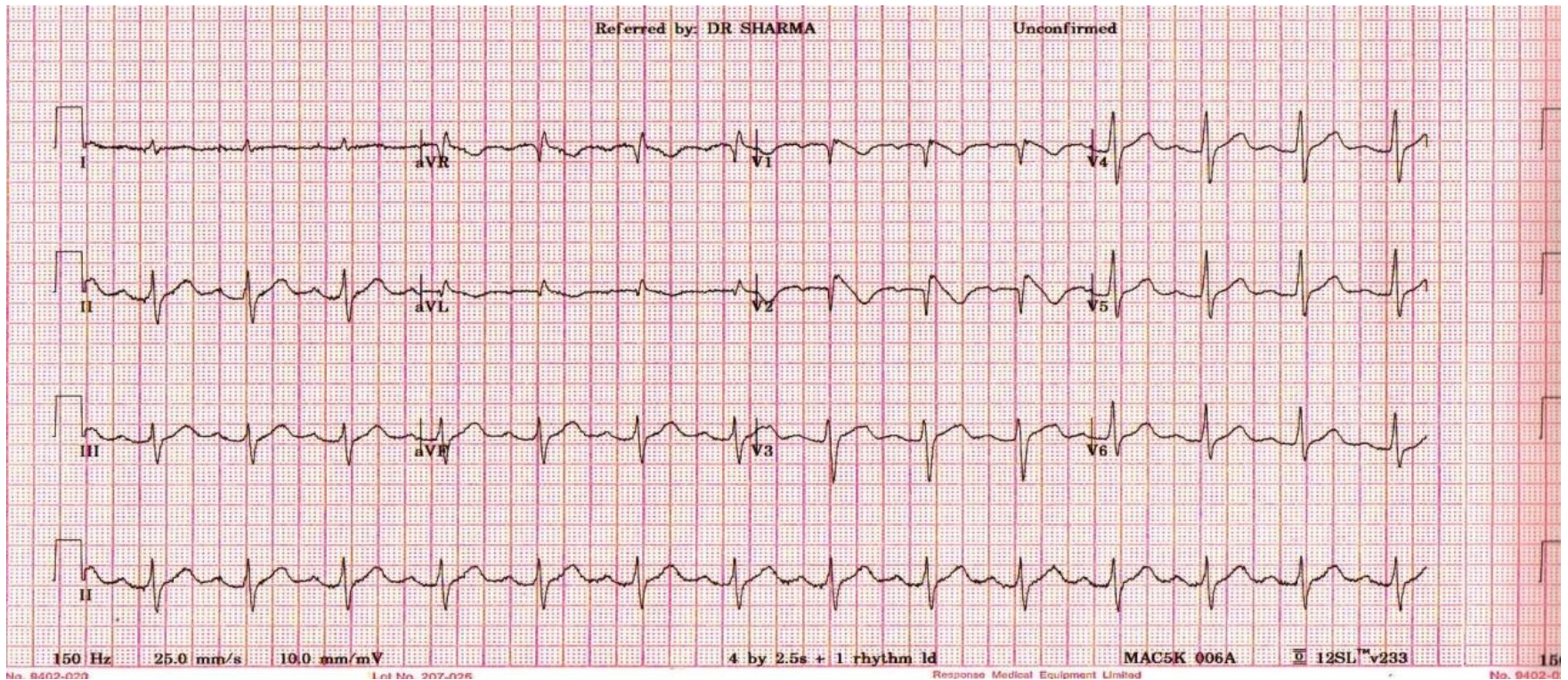
OR

Paradoxical prolongation of the QT interval with exercise

(Group 2)
Uncommon (< 5%)

- T-wave inversion
- ST-segment depression
- Pathological Q waves
- Left atrial enlargement
- Left axis deviation/left anterior hemiblock
- Right axis deviation/left posterior hemiblock
- Right ventricular hypertrophy
- Complete LBBB or RBBB
- Long or short QT interval
- Brugada-like early repolarization
- Ventricular arrhythmias

Brugada EKG Pattern

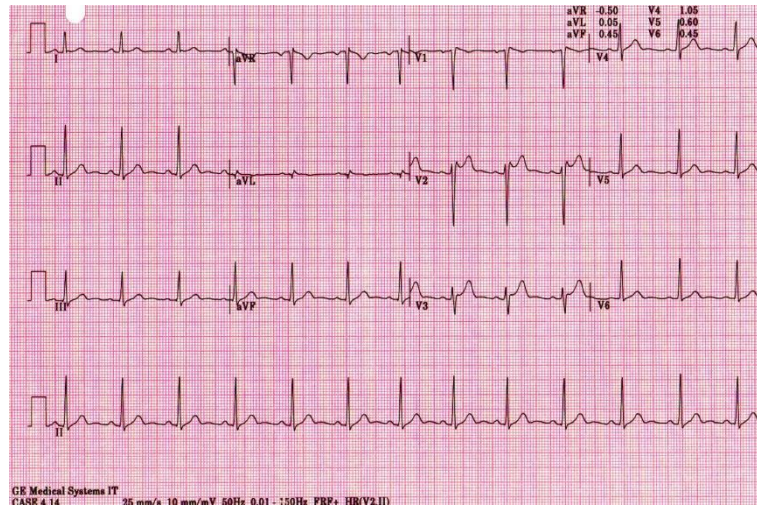


Message 11

Type 1 Brugada EKG pattern is abnormal.

Type 2 Brugada EKG pattern is non specific. Repeat ECG with V1 and V2 in higher intercostal leads. If there is no evidence of type 1 Brugada EKG, no further assessment required UNLESS there is a history of syncope or relevant family history.

Investigation of Type 2 Brugada Pattern



?Symptoms

?Family history

?Type 1 pattern in V1 and V2 in 2nd inter-costal leads

NO

Leave well alone

YES

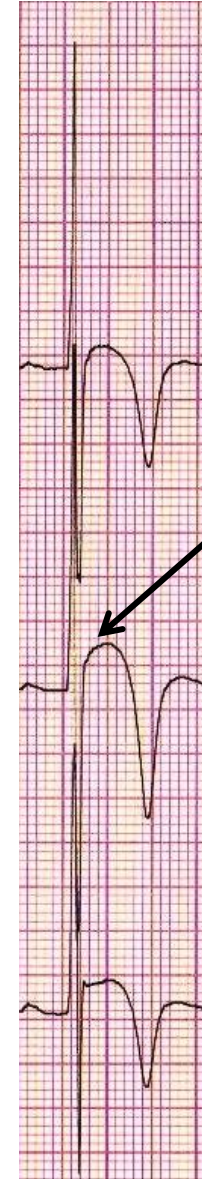
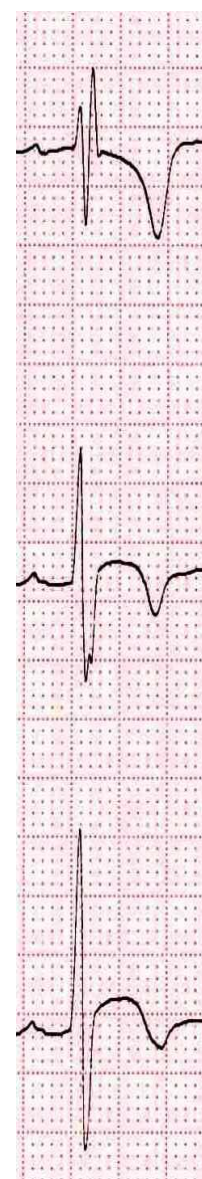
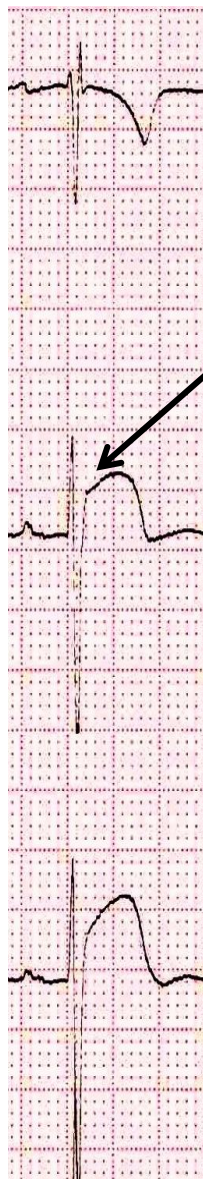
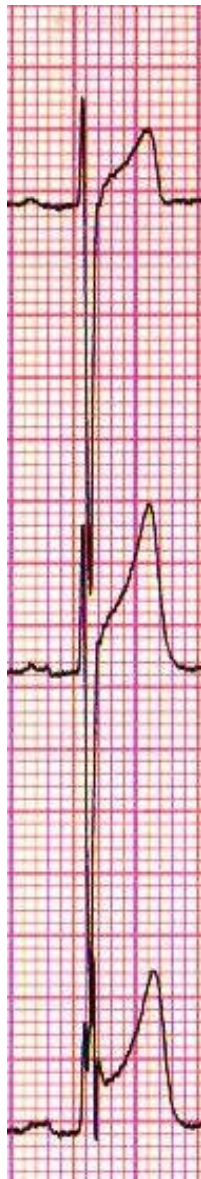
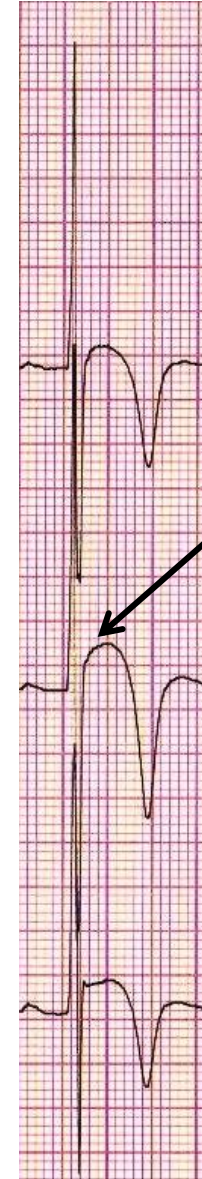
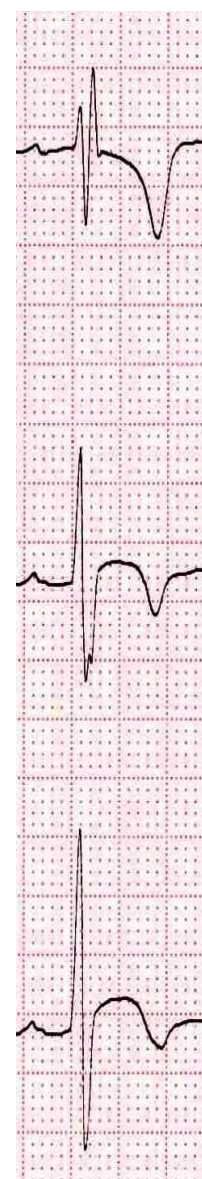
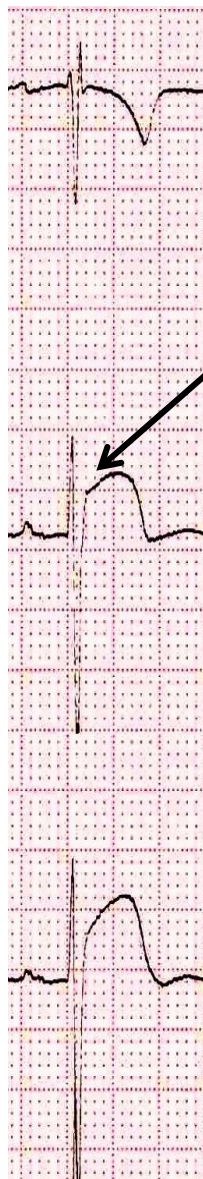
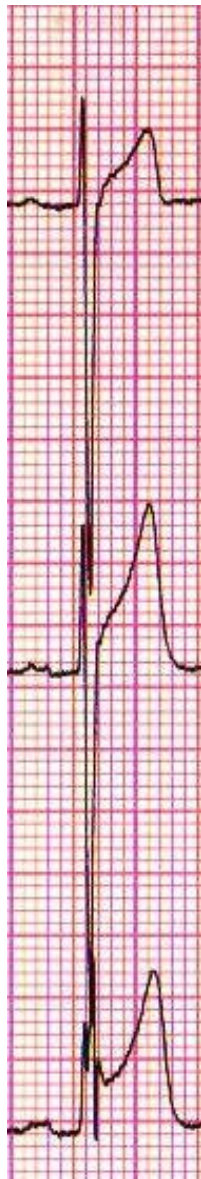
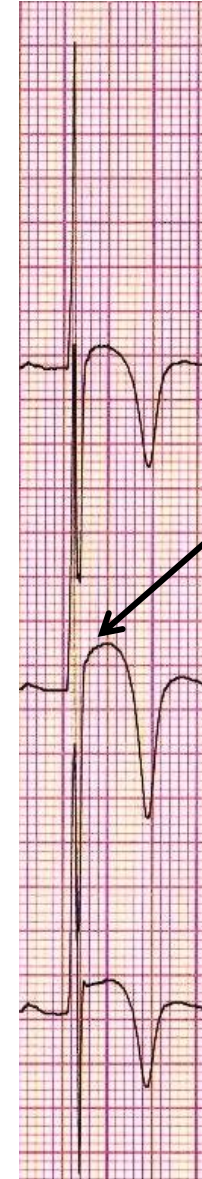
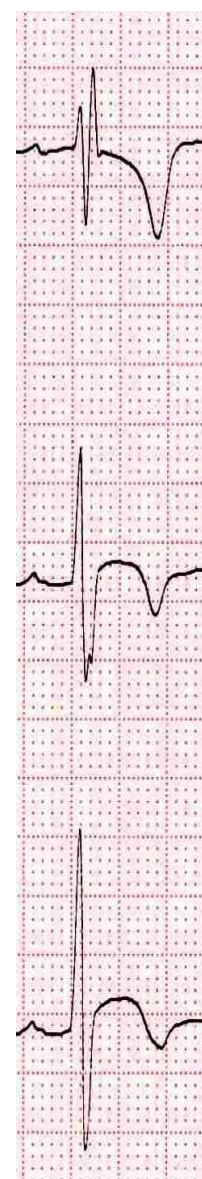
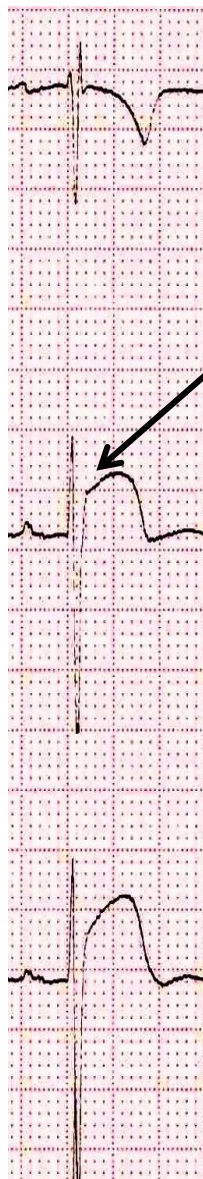
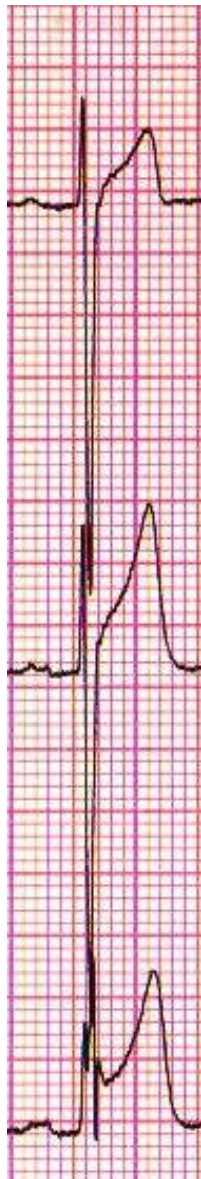
Provocation test

Anterior Precordial ECG Changes in Black Athletes

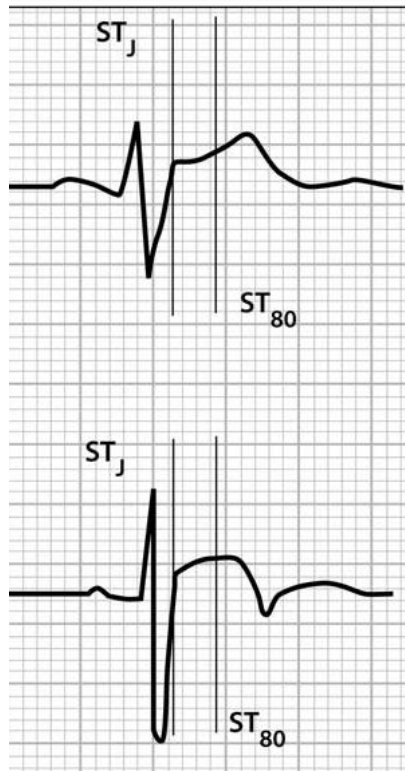
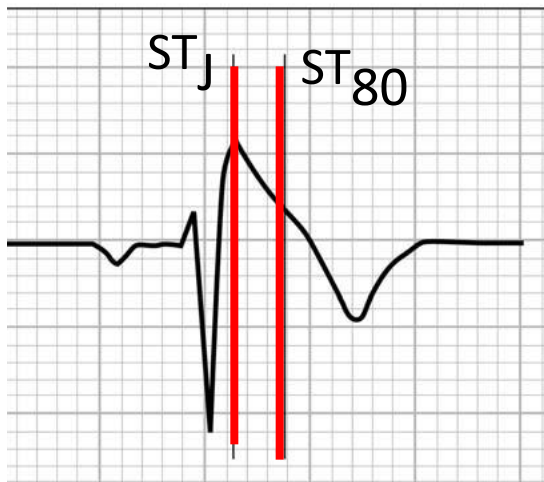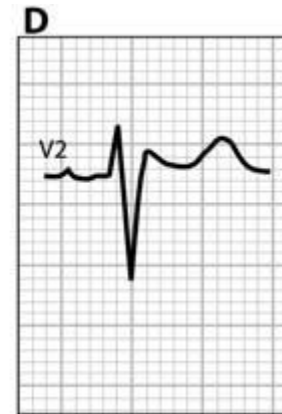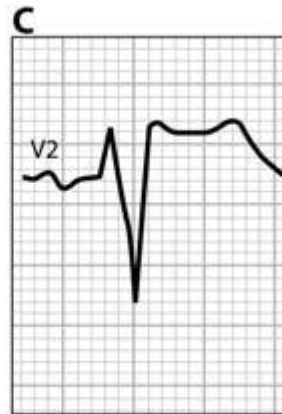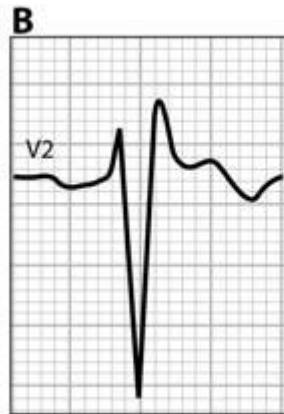
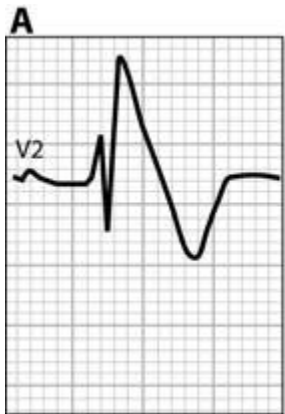V1

V2

V3



Athlete versus Brugada EKG



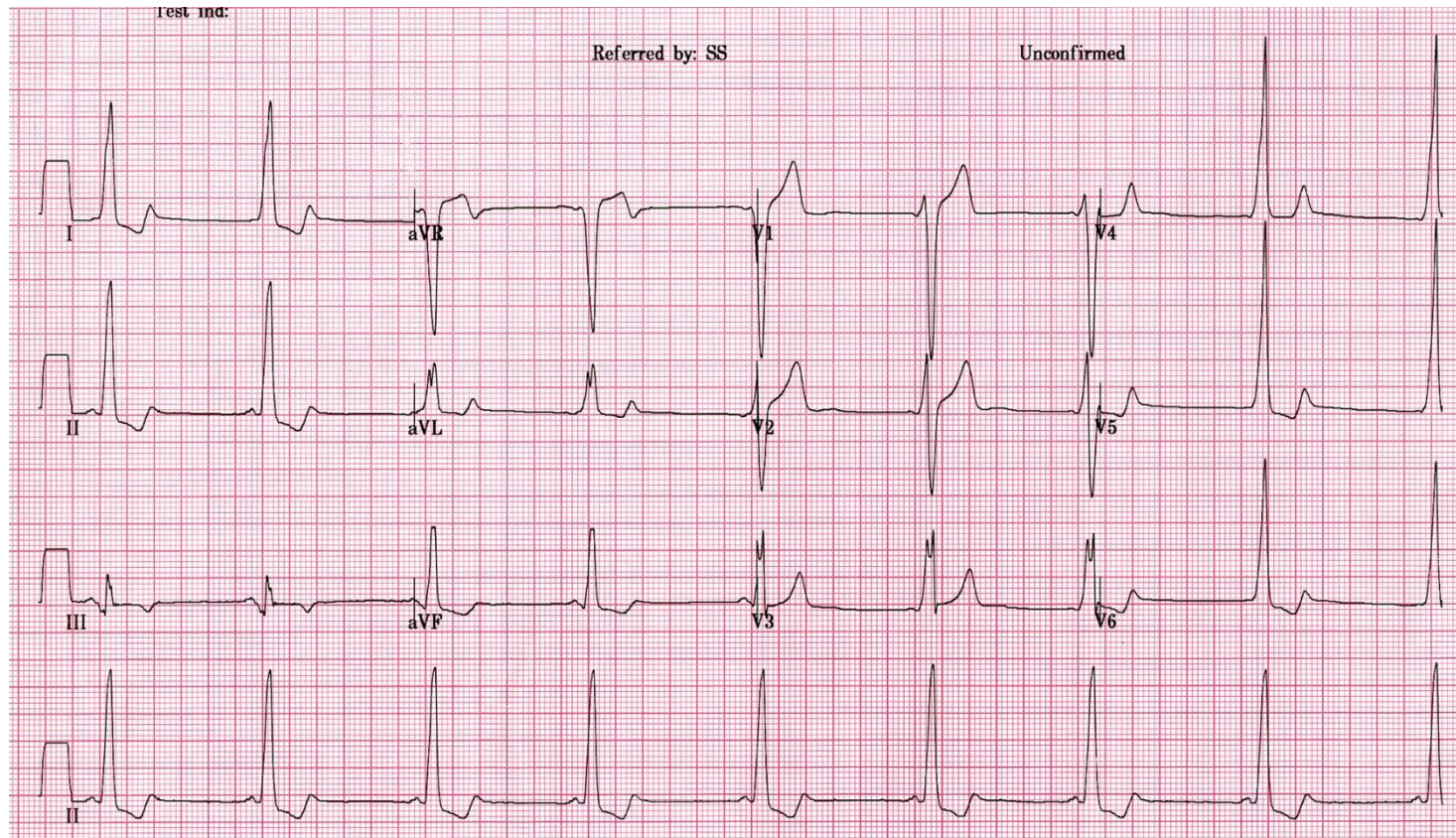
Brugada type A

ST_J: ST₈₀ > 1

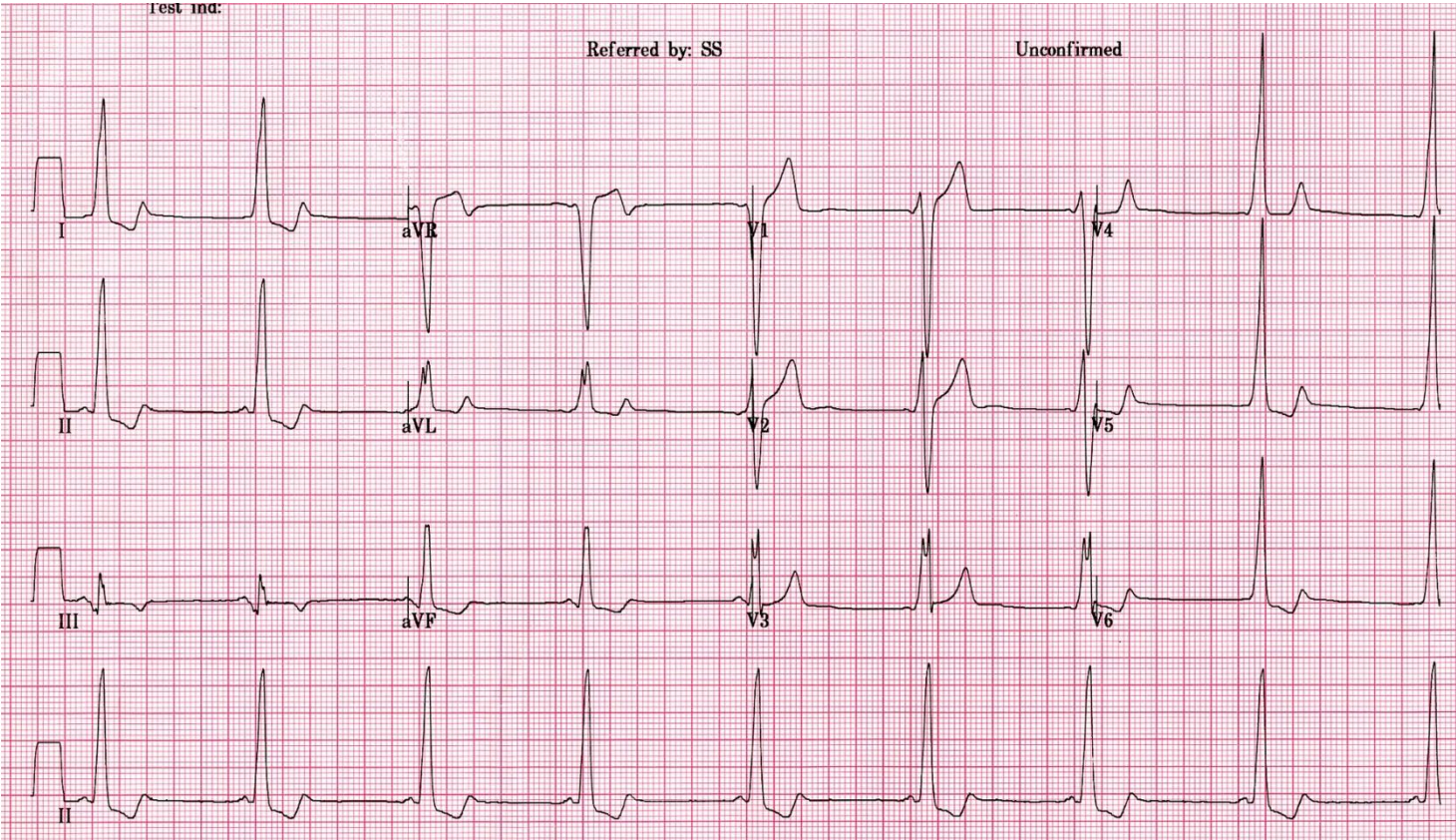
Athlete's Heart

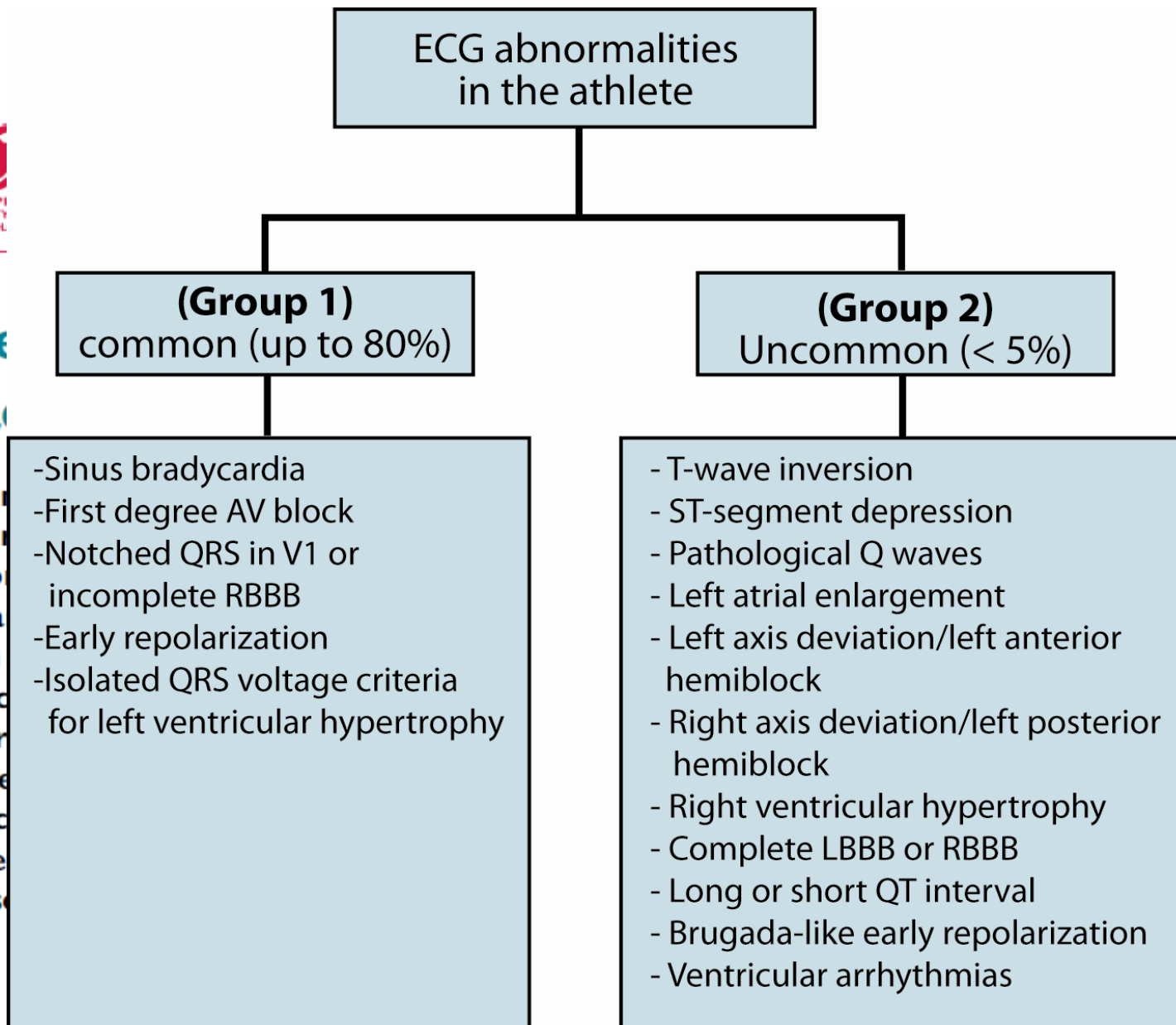
ST_J: ST₈₀ < 1

This is an EKG from an asymptomatic 24 year old basket ball player. Is further investigation required?



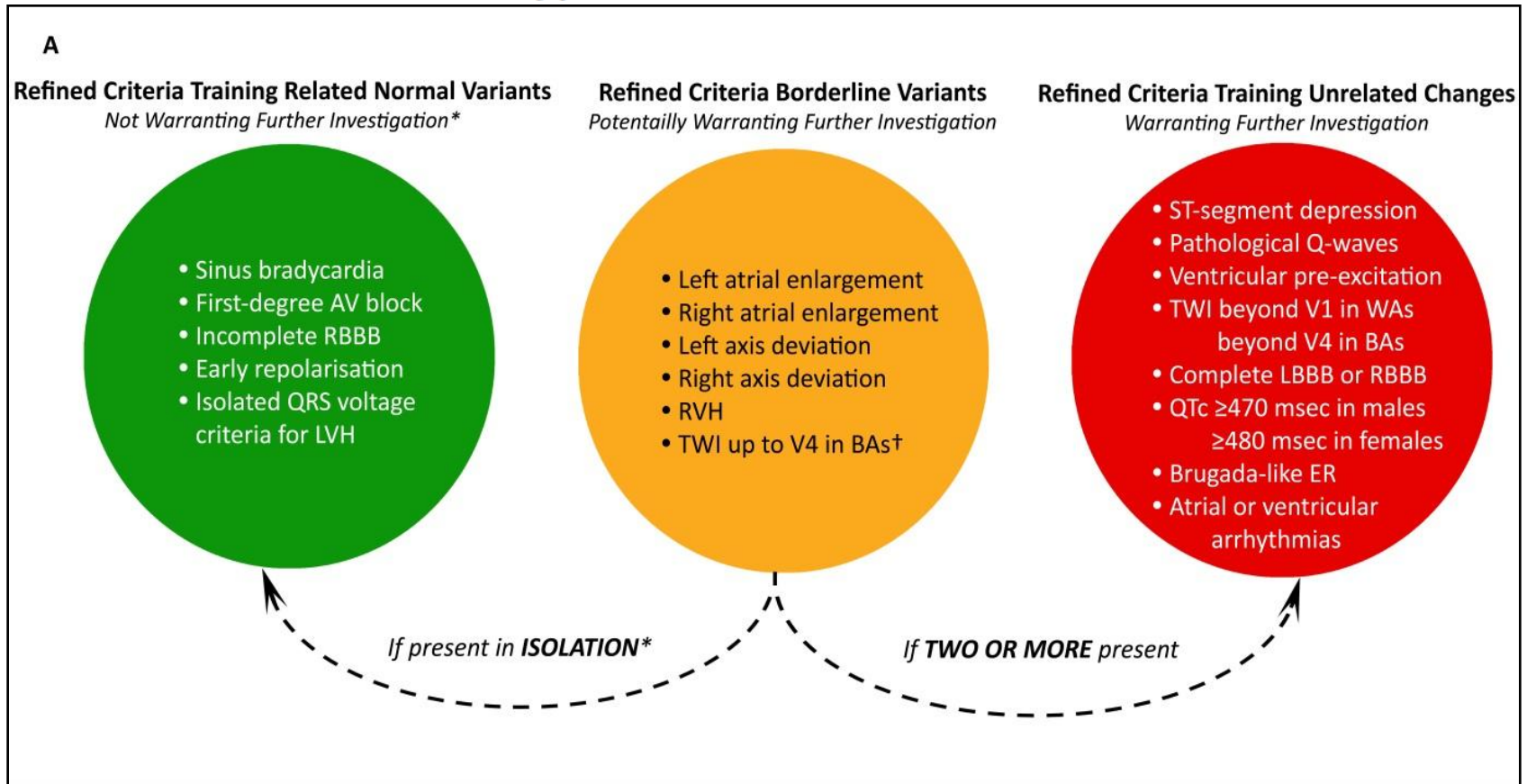
Wolff Parkinson White ECG





Comparison of Electrocardiographic Criteria for the Detection of Cardiac Abnormalities in Elite Black and White Athletes

Nabeel Sheikh, MRCP; Michael Papadakis, MRCP; Saqib Ghani, MRCP; Abbas Zaidi, MRCP; Sabiha Gati, MRCP; Paolo Adami, MD; François Carré, PhD; Frédéric Schnell, PhD; Mathew Wilson, PhD; Paloma Avila, MD; William McKenna, MD, DSc, FESC; Sanjay Sharma, MD, FRCP, FESC (UK)



Sensitivity and Specificity: ESC v Seattle v Refined

Parameter	Black athletes			White athletes		
	ESC	Seattle	Refined	ESC	Seattle	Refined

ALL DISEASE

Sensitivity (%)	70	70	70	60	60	60
Specificity (%)	40.3	79.3	84.2	73.8	92.1	94.1

SERIOUS DISEASE ONLY

Sensitivity (%)	100	100	100	100	100	100
Specificity (%)	40.1	79.3	84.2	73.1	92.1	93.9