

## EAE RECOMMENDATIONS

# Contrast echocardiography: evidence-based recommendations by European Association of Echocardiography

Roxy Senior<sup>1\*</sup>, Harald Becher<sup>2</sup>, Mark Monaghan<sup>3</sup>, Luciano Agati<sup>4</sup>, Jose Zamorano<sup>5</sup>, Jean Louis Vanoverschelde<sup>6</sup>, and Petros Nihoyannopoulos<sup>7</sup>

<sup>1</sup>Department of Cardiology, Northwick Park Hospital, Imperial College, London, Harrow HA1 3UJ, UK; <sup>2</sup>John Radcliffe Hospital, Oxford, UK; <sup>3</sup>King's College Hospital, London, UK; <sup>4</sup>La Sapienza University, Rome, Italy; <sup>5</sup>Hospital Clínico San Carlos, Madrid, Spain; <sup>6</sup>Cliniques Universitaires St-Luc, Université Catholique de Louvain, Brussels, Belgium; and <sup>7</sup>Hammersmith Hospital, Imperial College, London, UK

Received 30 December 2008; accepted 11 January 2009

### KEYWORDS

Contrast echocardiography;  
Recommendations

This paper examines the evidence for contrast echocardiography, both for improving assessment of left ventricular structure and function compared with unenhanced echocardiography and for the identification of myocardial perfusion. Based on the evidence, recommendations are proposed for the clinical use of contrast echocardiography.

## Introduction

In a significant proportion of patients, echocardiography fails to produce diagnostically useful images despite tissue harmonic imaging.<sup>1</sup> The main impediments appear to be obesity and lung disease.<sup>2</sup> The problem is even greater in patients referred for stress echocardiography as images are suboptimal in as many as 33% of the patients.<sup>3</sup> This results in inaccurate assessment of left ventricular (LV) function, and suboptimal reproducibility especially in the subgroup of patients with poor images, resulting in subsequent referrals for other tests because of uninterpretable images.

These concerns prompted the facilitation of contrast ultrasound imaging that utilizes contrast agents. The present generation of ultrasound contrast agents consist of microbubbles of encapsulated high-molecular-weight gas. Since the ultrasound characteristics of microbubbles are distinctly different from those of the surrounding blood cells and cardiac tissue, the backscatter that they produce result in intense echocardiographic signals, which are proportional to the blood volume. Thus, the LV cavity is enhanced compared with the surrounding heart muscle

(which has relatively lower myocardial blood volume). With the advancement in ultrasound techniques and improved microbubble technology, it is now possible also to assess myocardial microcirculation and hence perfusion.

This paper examines the clinical efficacy and safety of ultrasound contrast agents and proposes evidence-based recommendations and protocols for the use of contrast echocardiography in various clinical scenarios.

## Contrast agent

Echogenicity and ultrasound properties are determined by the size, shell, and encapsulated gas characterizing the microbubbles within the various contrast agents. Microbubble ultrasound scatter is proportional to the sixth power of the radius, so the largest bubble capable of passing through the pulmonary microcirculation will have the best acoustic profile.<sup>4</sup> The harmonic properties of microbubbles are a function of their non-linear oscillation, which means that they reflect sound not only at the fundamental frequency of the ultrasound source but also at higher harmonics.<sup>5</sup> A microbubble's ultrasonic characteristics also depend on its size, the composition of the outer shell of the bubble, and the encapsulated gas.<sup>5</sup> In general, the more elastic the shell, the more easily it will be compressed in an ultrasonic field and the better it will resonate. Conversely, stiffer shells may rupture when subjected to ultrasound.

\* Corresponding author. Tel: +44 20 8869 2547/2548; fax: +44 20 8864 0075.

E-mail address: roxysenior@cardiac-research.org

**Table 1** Characteristic of currently available contrast agents in UK and Europe

	SonoVue <sup>6</sup>	Optison <sup>7</sup>	Luminity <sup>8</sup>
Gas	Sulphur hexafluoride	Perfluoropropane	Perfluoropropane
Bubble size	2–8 µm	3.0–4.5 µm	1.1–2.5 µm
Surface coating	Surfactant/powder	Human albumin	Naturally occurring lipids
Contraindications and precautions			
Patients experiencing side effects in clinical trials (%)	11	17	8
Most frequent side effects in clinical trials	Headache (2.1%), nausea (1.3%), chest pain (1.3%), taste perversion (0.9%), hyperglycaemia (0.6%), injection site reaction 0.6%), paresthesia (0.6%), vasodilation (0.6%), injection site pain (0.5%).	Headache (5.4%), nausea and/or vomiting (4.3%), warm sensation or flushing (3.6%), dizziness (2.5%).	Headache (2.0%), flushing (1.0%), back pain (0.9%), rash/urticaria, wheezing/,allergic/anaphylaxis
Manufacturer	Bracco Diagnostics	GE Healthcare	Lantheus Medical Imaging (formerly Bristol-Myers Squibb)

The microbubbles must be stable enough to resist destruction at normal ultrasound power outputs and so maintain a sufficient concentration in the heart to give a satisfactory image. This is largely a factor of solubility of the gas in blood with high-molecular-weight bubbles being less soluble and so more stable.<sup>5</sup> Characteristics of the three-marketed second-generation contrast agents that use high-molecular-weight gases are listed in *Table 1*.<sup>6–8</sup>

### Contrast imaging modalities

As previously mentioned, harmonic imaging utilizes the non-linear scattering properties of ultrasound contrast agents to facilitate their detection within the heart. However, tissue also generates a harmonic signal as ultrasound is propagated through it and a high-quality contrast-enhanced image is one where the distribution of contrast (within the LV cavity and/or myocardium) is clearly seen without the presence of confounding myocardial tissue signals. The mechanical index (MI) is a measure of the power generated by an ultrasound transducer within an acoustic field. Harmonic imaging requires relatively high ultrasound power (high MI) that very quickly destroys (bursts) most commercially available ultrasound contrast agents and therefore is not a suitable imaging modality for continuous, or 'real-time' contrast imaging. High MI contrast imaging modalities have been successfully utilized for the detection of myocardial contrast using intermittent or triggered imaging modes where one imaging frame is created every one, two, three, or up to six cardiac cycles. The most common form of high MI imaging modality used in this way is harmonic power Doppler, which works best when utilized with a fragile contrast agent which is quickly destroyed and contains a soluble gas (air or nitrogen).<sup>9</sup> This typically involves a dual-pulse technique where the difference in backscattered signal from two high MI pulses transmitted down each scan line is examined. If contrast micro-bubbles are encountered by the first pulse, they will generate a backscattered signal and also be destroyed. In addition, any tissue targets will also generate a signal. The second pulse will only generate a signal from tissue because all contrast will have been destroyed by the first pulse. The backscattered data from

Pulse 1 are subtracted from that derived from Pulse 2, and the difference represents the contrast signal since the tissue signal cancels out. Newer high power techniques also utilize ultraharmonic properties of the microbubble, which improves the detection of the 'signal' of the microbubble, from the 'noise' of the background tissue, since tissue produces very little ultraharmonic signal.<sup>10</sup>

In order to use real-time imaging of contrast within the LV cavity and/or myocardium, it is necessary to reduce significantly the transmitted ultrasound power (low MI imaging) and this has required more sophisticated, contrast-specific imaging modalities.<sup>11</sup> These modalities have unique features, and have been named according to the developing ultrasound system manufacturer: power pulse inversion, power modulation, and cadence (or coherent) contrast imaging. They essentially work by transmitting multiple pulses down each scan line. Alternate pulses are 180° out of phase with other or vary in magnitude of amplitude by a fixed ratio, or are a combination of both strategies. All these types of modalities rely on the fact that tissue is essentially a linear and relatively predictable ultrasound scatterer, especially at low ultrasound energy levels, whereas contrast microbubbles are not, and are therefore described as being 'non-linear'. When alternate backscattered signals are received, which are perfectly out of phase or proportionally altered in amplitude, they are processed by the imaging software as being derived from tissue and therefore are filtered out and suppressed. All remaining 'non-linear' signals are considered to be derived from contrast microbubbles and are displayed. When using this kind of imaging modality, the image will normally be totally dark prior to contrast administration, confirming effective suppression of tissue data. This type of imaging is very effective for LV endocardial border enhancement, as it demonstrates a sharp demarcation between the contrast-enhanced cavity and the myocardium. With minor modification and increased contrast concentration, it can also effectively detect and display contrast within the myocardium, facilitating the evaluation of myocardial perfusion as described later.<sup>11</sup> It is common to combine this form of low MI contrast imaging with a burst of a few frames of high MI imaging to destroy contrast within the myocardium.

This allows the qualitative and quantitative assessment of contrast replenishment into the myocardium and is also discussed later.

## Efficacy of contrast agents in echocardiography

### Enhancement of left ventricular endocardial border

In all of the following studies described, all patients had sub-optimal images with non-contrast echocardiography before the use of a contrast agent. There have been three controlled studies of SonoVue in echocardiography.<sup>6</sup> A total of 317 patients were treated with doses of SonoVue (between 0.5 and 4.0 mL) or with a comparator drug that was an older microbubble contrast agent or saline. Primary endpoints were assessed by two blinded readers. In all three studies, SonoVue administration resulted in increases in endocardial border delineation (EBD) score and left ventricular opacification (LVO) score relative to baseline images, which were significantly greater than after administration of the comparator or saline ( $P < 0.001$ ). In the two studies in which it was a primary endpoint, duration of useful contrast was 1.7–4 min with SonoVue (2.0 mL) compared with <15 s with the highest dose of comparator. For all primary endpoints (LVO and EBD scores, and duration of effect), the maximum effect observed with SonoVue was significantly greater than that achieved with the comparator.

Optison and Alburnex were used in two similar multicentre, randomized crossover studies.<sup>7</sup> The test drugs were administered single blind and the image analysis was performed double blind. A total of 203 patients participated with the criteria for inclusion being that at least two of six segments of the LV endocardial border were not well delineated at routine echocardiography. Images were interpreted by a reader who was blinded to the patient's clinical history and to the identity and dose of the test drug. In comparison with non-contrast ultrasound, Optison significantly increased the length of endocardial border that could be visualized both at end-systole and end-diastole. In addition, Optison significantly improved the ability to delineate qualitatively each of the LV segments, with a lesser effect for the septal segments. As assessed by video densitometry, Optison increased LV opacification in the mid-chamber and apical views.

Four controlled studies were performed with Luminity in a total of 249 patients with two or more non-evaluable

segments on non-contrast echocardiography. Outcomes were assessed both by the institutional investigator and by blinded, independent physicians or sonographers who had no clinical information available to them. A primary endpoint in all studies was change in EBD from baseline, and significant improvements in this parameter were seen by a total of 12 of 16 of the blinded readers.<sup>12</sup> In three studies, involving 190 patients in total, LV enhancement was also a primary endpoint. In two of the studies, blinded readers reported enhancement in up to 78% of participants. In the remaining study, the ability of investigators to optimize echocardiographic equipment settings led to even better results with blinded readers reporting 86–98% enhancement.<sup>12</sup> An overview of the studies providing proof of contrast enhancement of endocardial border definition in echocardiography is provided in *Table 2*.

### Quantitative assessment of left ventricular function

Left ventricular function assessment provides valuable diagnostic and prognostic information in patients with suspected cardiovascular disease. Accurate and reproducible measurement of LV function is imperative for reliability of information. Several studies, as shown in *Table 3*, have indicated that contrast-enhanced echocardiography improves the evaluation of LV volumes and ejection fraction (LVEF).<sup>13–22</sup> These findings were most striking in study participants who had two or more adjacent poorly visualized segments.

However, in a larger study consisting of 110 patients, the accuracy of intravenous contrast echocardiography was found to be significantly better than unenhanced tissue harmonic imaging when compared with cardiac magnetic resonance (CMR) imaging irrespective of imaging quality.<sup>18</sup> It is now known based on contrast studies that LV volumes assessed by tissue harmonic imaging were consistently smaller, while those assessed during contrast echocardiography were more comparable with cardiac MRI. This is probably because tissue harmonic imaging does not track the true endocardial surface as well as contrast echocardiography, resulting in tracking noise in the LV cavity that is perceived as the endocardial border. In a multicentre study<sup>19</sup> using SonoVue, LV volumes and LVEF assessed by contrast echocardiography demonstrated the least reader variability compared with unenhanced echocardiography, cine ventriculography, and cardiac MRI. When regional function was

**Table 2** Efficacy of contrast agents on various measures of image enhancement in echocardiography (Modified from Bhatia and Senior)<sup>102</sup>

Study	Patients (n)	Contrast agent used vs. comparator or control	Measure of contrast enhancement					
			LVB length	LVO	LVEB score	Duration of contrast effect	Salvage of non-diagnostic echo	Side effect profile
Cohen <i>et al.</i> <sup>94</sup>	203	Optison vs. Alburnex	↑	↑		↑		↔
Senior <i>et al.</i> <sup>95</sup>	218	Sonovue			↑		↑	↔
Kitzman <i>et al.</i> <sup>96</sup>	211	Luminity		↑		↑	↑	↔
Nguyen <i>et al.</i> <sup>97</sup>	40	Optison			↑		↑	
Nanda <i>et al.</i> <sup>98</sup>	138	Sonovue vs. Alburnex vs. saline		↑	↑	↑		↔
Rizzo <i>et al.</i> <sup>99</sup>	40	Sonovue			↑			

Upward arrows signify significant improvement and horizontal arrows signify no significant difference in side effects compared with control. LVB, left ventricular border; LVO, left ventricular opacification; LVEB, left ventricular endocardial border delineation score.

**Table 3** Efficacy of contrast echocardiography for the assessment of left ventricular ejection fraction volumes or regional wall motion abnormalities (Adapted from Bhatia and Senior)<sup>102</sup>

	Patients (n)	Comparator	Unenhanced imaging mode	Contrast agent	Agreement vs. comparator*		P-value
					Without contrast	With contrast	
Hundley <i>et al.</i> <sup>13</sup>	40	CMR	FI	EchoGen	<b>0.85</b> (EF) <b>0.92</b> (EDV) <b>0.94</b> (ESV)	<b>0.93</b> (EF) <b>0.95</b> (EDV) <b>0.97</b> (ESV)	<0.03 <0.02 <0.01
Reilly <i>et al.</i> <sup>14</sup>	70	<sup>a</sup>	HI	Optison	62% (EF)	91% (EF)	<0.0001
Nahar <i>et al.</i> <sup>15</sup>	50	RNI	HI	Optison	<b>0.84</b> (EF)	<b>0.96</b> (EF)	
Yu <i>et al.</i> <sup>16</sup>	51	RNI	HI	Levovist	<b>0.89</b> (EF) <b>0.71</b> (EDV) <b>0.89</b> (ESV)	<b>0.97</b> (EF) <b>0.93</b> (EDV) <b>0.97</b> (ESV)	
Yong <i>et al.</i> <sup>17</sup>	32	TEE	HI	Optison	<b>0.83</b> (EF) 58% RWMA	<b>0.91</b> (EF) 70% RWMA	
Malm <i>et al.</i> <sup>18</sup>	110	CMR	HI	Luminity Sonovue	71% EDV 80% ESV 92% EF	85% EDV 90% ESV 97% EF	
Hoffmann <i>et al.</i> <sup>19</sup>	120	CMR <sup>b</sup>	HI	Sonovue	kappa 0.43 RWMA	kappa 0.77 RWMA	<0.05
Lim <i>et al.</i> <sup>20</sup>	36	CMR	HI	Sonovue	69% (EF) kappa 0.33	83% (EF) kappa 0.66	
Weiss <i>et al.</i> <sup>21</sup>	560	<sup>c</sup>	HI	Luminity	63% <sup>c</sup> (RWMA)	95% <sup>c</sup> (RWMA)	P<0.0001
Overall total	1069						
Mean correlation coefficient [95% CI]					<b>0.85</b> (EF)[0.82–0.88] <b>0.81</b> (EDV)[0.6–1.02] <b>0.92</b> (ESV)[0.87–0.97]	<b>0.94</b> (EF)[0.91–0.97] <b>0.94</b> (EDV)[0.92–0.96] <b>0.97</b> (ESV)	
Mean % agreement with gold standard					77% (EF) 61% (RWMA)	94% (EF) 83% (RWMA)	

Figures in bold refer to correlation coefficient. Percentage values refer to mean extent of agreement with standard unless otherwise stipulated.

RNI, radionuclide imaging; TEE, transoesophageal echocardiography; LV, left ventricle; EDV, end-diastolic volume; ESV, end-systolic volume; EF, ejection fraction; RWMA, regional wall motion abnormalities; FI, fundamental imaging; HI, harmonic imaging; CMR, cardiac magnetic resonance imaging.

<sup>a</sup>No gold standard: direct comparison between standard, harmonic, and contrast echo. Values refer to percentage of patients in whom EF could be calculated with certainty.

<sup>b</sup>Expert panel decision as gold standard, but patients also underwent CMR. Values refer to Kappa extent of agreement with expert panel consensus.

<sup>c</sup>Values refer to percentage of diagnostic stress echocardiograms in difficult-to-image patients within a trial.

evaluated, the assessment by contrast echocardiography demonstrated the highest accuracy compared with cardiac MRI or cineventriculography. Such results have major implications for screening patients before and following them up after chemotherapy, because one needs the most reproducible technique to track changes in LV function so that timely action may be taken. In this scenario, contrast echocardiography is likely to be the non-invasive technique of choice due to its low risk (non-ionizing) and portability.

The ability of contrast echocardiography to assess LV remodelling, a major indicator of prognosis, 7–10 days after acute myocardial infarction (AMI) was evaluated.<sup>20</sup> Compared with cardiac MRI, the study demonstrated that contrast echocardiography was more accurate and reproducible than tissue harmonic imaging alone. Furthermore, contrast echocardiography correctly identified patients with various grades of LVEF. Such findings are clinically important because LVEF after AMI is one of the major determinants not only of outcome but also for decision-making regarding, for example, the implantation of an expensive, but life saving, device like intracardiac cardioverter defibrillator (ICD).

The accuracy of contrast echocardiography for assessing LV volumes and LVEF was also demonstrated in critically ill patients in intensive therapy units where accurate assessment of LV function is mandatory for optimal management but often has to be performed under adverse imaging circumstances.<sup>17</sup> In addition, it has been shown that contrast echocardiography improves the interpretation of regional and global LV function in intensive care unit patients.<sup>14</sup> In a further evaluation of similar group of patients, comparing the results with transoesophageal echocardiography, it was concluded that the use of intravenous contrast harmonic echocardiography significantly improved the feasibility and accuracy of estimated LVEF over tissue harmonic imaging.<sup>17</sup>

A randomized study evaluated the use of Luminity for the detection of coronary artery disease (CAD) in 560 patients in whom non-contrast stress echocardiography had given difficult-to-interpret images.<sup>21</sup> Patients were randomized to receive rest and stress echocardiography either enhanced with Luminity or unenhanced. Investigator confidence was assessed as excellent or good in 95% of the enhanced images compared with only 63% of unenhanced images ( $P < 0.0001$ ). Of the enhanced images, 95% proved diagnostic compared with 66% of unenhanced images. Three months after the imaging, 36% of patients with unenhanced imaging

had required further diagnostic testing compared with only 17% of those with enhanced images.

It has been estimated that the addition of contrast media gives ~37% more diagnostic information and, in patients with a poor acoustic window, 50–90% improvement has been observed.<sup>22</sup> In addition, it has been pointed out that contrast agents enhance decision-making for echocardiographers and clinicians as well as shortening the time to diagnosis.<sup>22</sup> Contrast enhancement may also improve clinical throughput by decreasing the time needed to image difficult-to-image patients.<sup>22</sup>

### Clinical efficacy of stress contrast echocardiography

That contrast administration improves image quality through improved endocardial border definition during stress echocardiography has been shown in many studies (Table 4). Image quality is a key factor determining the diagnostic accuracy of stress echocardiography. Contrast has been shown to improve visualization of regional wall motion abnormalities, improve study quality, and increase reader confidence in study interpretation.<sup>23–25</sup>

Moir *et al.*<sup>26</sup> demonstrated improved sensitivity and accuracy for the detection of CAD when contrast was administered. Studies have compared the sensitivity and specificity of dobutamine stress echocardiography in patients with good LV visualization at rest with that in patients with poor image quality during native imaging that underwent contrast echocardiography.<sup>23,27</sup> These investigators found that, in patients with poor image quality, the use of contrast during dobutamine stress echocardiography significantly improved EBD and resulted in a sensitivity and specificity for the detection of CAD comparable with that achieved with the native dobutamine stress in patients with good image quality. In a recent randomized control trial by Plana *et al.*<sup>28</sup> comparing the diagnostic accuracy for the detection of CAD in patients who received contrast vs. those who did not, accuracy of contrast dobutamine stress echocardiography was significantly higher compared with unenhanced stress echocardiography for the detection of CAD.

In another study, stress echocardiography with contrast (30% of patients) resulted in reduced down stream cost compared with Ex-ECG for the detection of CAD in patients

**Table 4** Contrast for endocardial border delineation in stress echocardiography

Type of study	Method	Number of subjects	Contrast	Study
Single centre	Dobutamine	117	Optison	Dolan <i>et al.</i> <sup>23</sup>
Single centre	Treadmill exercise	100 <sup>a</sup>	Optison	Shimoni <i>et al.</i> <sup>24</sup>
Single centre	Dobutamine	300	Optison	Rainbird <i>et al.</i> <sup>25</sup>
Single centre	Dipyridamole	70 <sup>a</sup>	Definity	Moir <i>et al.</i> <sup>26</sup>
Single centre	Dobutamine	1486 <sup>a</sup>	Definity Optison	Tsutsui <i>et al.</i> <sup>100</sup>
Single centre	Dobutamine	893	Levovist	Wake <i>et al.</i> <sup>101</sup>
Single centre	Dipyridamole	120 <sup>a</sup>	Optison	Korosoglou <i>et al.</i> <sup>102</sup>
Single centre	Dobutamine	30	Infuson	Ikonomides <i>et al.</i> <sup>103</sup>

Definity, perflutren lipid microspore; Levovist, galactose/palmitic acid microcrystal suspension; Optison, perflutren protein-type A microspheres; Sonazoid, DB723/NC100100, perflubutane microspheres.

<sup>a</sup>Also perfusion.<sup>91</sup>

presenting with troponin negative acute chest pain and enabled more patients to be discharged rapidly from the hospital.<sup>29</sup> A study in the USA estimated that by reducing the need for further investigative procedures, contrast enhancement of sub-optimal images during stress echocardiography would result in a saving of \$238 per patient.<sup>30</sup>

Studies have also shown that the inter-observer variability improved significantly following contrast administration for the interpretation of wall motion abnormalities and this is particularly true if the operators are in their learning phase.<sup>27,31</sup>

## Assessment of cardiac structure

Contrast echocardiography is now recognized as the technique of choice for establishing or excluding the presence of apical hypertrophic cardiomyopathy, LV thrombus, non-compaction of LV, and life-threatening complications of myocardial infarction, such as myocardial rupture and LV pseudoaneurysm.<sup>32-35</sup> Contrast opacification facilitates the identification of apical abnormalities. This is because native tissue harmonic echocardiography is unable to overcome the noise, clutter, and reverberation artefacts in the near field as tissue harmonic signals are weak at the nearfield; hence, apical abnormalities can be difficult to visualize.

## Clinical safety of contrast agents in echocardiography

Contrast echocardiography is safe. In a large retrospective analysis of >18 000 patients, of which one-third received contrast agent in the acute setting, there was no significant difference in mortality in patients who received contrast vs. those who did not.<sup>36</sup> This is because patients who received contrast agents had a higher risk clinical profile, compared with those who did not receive contrast. A European stress echocardiography study included patients receiving Optison, SonoVue, or no contrast, and found that the overall incidence of adverse events was not different between the three groups.<sup>37</sup> Another UK study involving ~4000 patients showed no difference in acute complication rate in patients who received contrast vs. those who did not during stress echocardiography and this is despite the fact that the patients in the contrast group were in the higher risk group.<sup>38</sup> A study in the USA included 963 patients receiving Optison and 523 receiving Luminity during stress echocardiography and analysed adverse cardiovascular and pulmonary effects.<sup>39</sup> The incidence of side effects did not differ significantly between the three groups (Optison, Definity, and no contrast). Finally, a recent report of dobutamine myocardial stress echocardiography of over 5000 patients showed no excess of side effects.<sup>40</sup> Side effects have been noted with contrast agents but they are usually mild and transient (*Table 1*). However, serious allergic reactions have been observed, at a very low incidence (estimated to be ~1:10 000). *Table 5* lists mortality observed during usage of competing investigations.<sup>41</sup> Therefore, the evidence shows that contrast echocardiography is very safe in clinical practice. Except for SonoVue, both Optison and Luminity may be used in acute coronary syndromes (ACS). The contraindication on the use of contrast agents (Definity and Optison) in acute cardiac conditions was recently

**Table 5** Comparative mortality in selected cardiac procedures

Procedures	Mortality
Contrast Echo	1:145 000 (SonoVue), 1:500 000 (Definity)
Myocardial Scintigraphy	1:10 000
Exercise ECG	1:2500 (or AMI)
Coronary arteriography	1:1000

Modified from Main *et al.*<sup>41</sup>

withdrawn by FDA following mounting evidence of safety and unequivocally favourable risk-benefit profile in the acute setting.<sup>36,38,42</sup> It is hoped that EMEA will follow suit, regarding Sonvue which has similar safety profile to Definity and Optison.<sup>37,38</sup> At present, SonoVue may be used 7 days after ACS. However, in all acute conditions, it is important to monitor vital signs and pulse oximetry for 30 min after contrast administration. The only absolute contraindications for administration of contrast agents are in patients with known or suspected intracardiac cardiac shunting of significant degree, or known hypersensitivity to the agent. Intra-coronary administration is also not approved and is considered contraindicated, although it has been done without complications in thousands of patients with hypertrophic cardiomyopathy undergoing septal ablation.

## Indications, imaging modality, and contrast administration for left ventricular opacification

### Indications for resting left ventricular opacification contrast echo<sup>2</sup>

In patients with suboptimal images:

- (1) To enable improved endocardial visualization and assessment of LV structure and function when two or more contiguous segments are NOT seen on non-contrast images
- (2) To have accurate and repeatable measurements of LV volumes, and ejection fraction by 2D Echo
- (3) To increase confidence of the interpreting physician in the LV function, structure and volume assessments
- (4) To confirm or exclude the echocardiographic diagnosis of the following LV structural abnormalities, when non-enhanced images are suboptimal for definitive diagnosis:

- apical hypertrophic cardiomyopathy
- ventricular non-compaction
- apical thrombus
- ventricular pseudoaneurysm

### Indications for use of contrast in stress echocardiography

When two or more endocardial border contiguous segments of LV are not well visualized in order to:

- To obtain diagnostic assessment of segmental wall motion and thickening at rest and stress
- To increase the proportion of diagnostic studies
- To increase reader confidence in interpretation

**Table 6** Imaging modalities

Power MI)	Type of imaging	Technology	Advantages	Disadvantages
High (0.8–1.0)	Intermittent	Power Doppler ultraharmonics	Very sensitive for detection of contrast	Cannot assess wall motion simultaneously
Low (0.1–0.3)	Continuous (real time)	Power modulation Power pulse inversion Cadence pulse sequencing (or coherent contrast imaging)	Wall motion can be assessed simultaneously	Less sensitive for detection of contrast

## Imaging modalities

### High mechanical index imaging

Harmonic imaging has become the standard imaging technique for native (tissue) echocardiography, although it was originally developed to enhance the detection of contrast agents (Table 6). In order to use it optimally for contrast studies, the transmit power must be reduced from an MI >1.0 to ~0.4–0.6. However, even this power level is still relatively high and can cause destruction of the contrast in the nearfield of the transducer as well as create confounding tissue signals in the myocardium, which impair the delineation of the endocardium.

### Low power imaging

For clinical studies, the newer contrast-specific imaging modalities (Pulse inversion Power Modulation and Cadence Pulse Sequencing) are preferable. This low-power ('Low MI') contrast-specific imaging technology provides the best LV opacification (homogeneous contrast, excellent endocardial border definition). Because of the low transmit power, less contrast is needed compared with standard real-time harmonic imaging. In addition, myocardial opacification, which allows assessment of perfusion, can be studied simultaneously. Thus, perfusion can be assessed without prolongation of the LVO contrast study and without increasing the amount of contrast agent infused. Scanning with the new low-power contrast-specific imaging modalities for the detection of myocardial perfusion is an 'off-label' application, as none of the currently available contrast agents have been approved for this indication. It should be noted, however, that because the real-time Low MI modes transmit multiple pulses down each image scan line, relatively low frame rates may result, which are not optimal for wall motion assessment. This may be usually overcome by narrowing the sector width until the frame rate is at least 25 Hz that is preferable for wall motion assessment during stress echocardiography.

Low MI contrast-specific techniques display the contrast within the cavities of the heart and, because contrast microbubbles are red blood cell tracers, they accurately display the myocardial blood within the intramyocardial vessels. The blood volume within the myocardial vessels comprises only 7% of the myocardium. Therefore, the myocardial opacification is always much less intense than the cavity opacification, providing an excellent contrast for endocardial delineation. The myocardial contrast is also very useful for assessing thickening of the myocardium and myocardial perfusion.

## Contrast administration

### Infusion method

Infusion of ultrasound contrast agents requires an infusion pump that is not limited by the detection of microbubbles, and which may be intermittently agitated to maintain heterogeneity of distribution of the microbubbles. Agitation can be performed manually by slowly rocking the pump to and fro. A special infusion pump has been developed for SonoVue, which provides constant agitation. The pump can be prepared in a few minutes prior to the study while the patient undresses or during the baseline echo examination. By an alternating rotating action the contrast agent is agitated preventing bubbles separating and floating to the surface. The pump is then kept in a *stand-by* mode. The pump is started by the sonographer using a remote control and no additional staff is needed. Although the pump provides the possibility of an initial small bolus, a constant infusion of Sonovue 0.8 mL/min from the start is usually satisfactory and need not be changed in the majority of patients. In contrast to a bolus injection, a continuous infusion over a short time provides stable conditions to acquire loops from different scanplanes and provides a steady-state level to quantitatively assess myocardial perfusion. During stress echocardiography, the infusion can be stopped at any time and resumed when needed. Between infusion periods, the contrast agent is gently agitated. The contrast infusion is connected through a three-way-tap or small bore Y connector at the IV cannula, permitting the simultaneous infusion during dobutamine stress echocardiography.

### Bolus injection

It is also possible to use slow bolus injections (~0.2 mL) of all agents (Sonovue, Luminity, and Optison) followed by slow 5 mL saline flush over 20 s. However, these are not as controllable or reproducible as infusion.

## Myocardial contrast echocardiography

### Physiologic basis of myocardial contrast echocardiography

The predominant (90%) component of myocardial blood volume resides within the capillaries.<sup>43</sup> The myocardial signal assessed visually as contrast intensity reflects the concentration of microbubbles within the myocardium.<sup>44</sup> When the entire myocardium is fully saturated during a continuous infusion of microbubbles, the signal intensity denotes the capillary blood volume. Any alteration of signal in such a situation must, therefore, occur predominantly from a change in capillary blood volume. Furthermore, it has

been shown that following destruction, or depletion, of microbubbles in the myocardium during high-power imaging, replenishment of contrast within the myocardium can be observed.<sup>44</sup> The capillary blood velocity is 1 mm/s with an ultrasound beam elevation of 5 mm. Thus, it takes ~5 s for complete replenishment of the myocardium. Any decrease in myocardial blood flow (MBF) prolongs replenishment time in proportion to the reduction in MBF.<sup>45</sup> Myocardial perfusion is defined as tissue blood flow at the capillary level. The two components of tissue blood flow are capillary blood volume and red blood cell velocity. As microbubbles have been shown to be red blood cell flow tracers, the product of peak microbubble intensity (representative of myocardial blood volume) and their rate of appearance (representative of blood velocity) equals MBF.<sup>45</sup> Therefore, myocardial contrast echocardiography (MCE) can detect capillary blood volume and, by virtue of its temporal resolution, can also assess MBF. This imaging technique of 'destruction (or depletion) and replenishment' requires the delivery of a series of high-energy ultrasound pulses to destroy (deplete) microbubbles in the myocardium. Ultrasound imaging is then continued either intermittently (during high-power imaging) or continuously (during low-power imaging) to observe contrast intensity and microbubble velocity.

### Detection of coronary artery disease

At rest, normally perfused myocardium demonstrates appearance of contrast within five cardiac cycles during a destruction/replenishment acquisition; after stress, this is reduced to two cardiac cycles, due to increased MBF. A delayed contrast appearance due to reduced blood flow velocity and reduced contrast intensity due to decreased capillary blood volume forms the basis for detection of CAD using MCE.<sup>43</sup> Single-photon emission computed tomography (SPECT) using radionuclide agents such as <sup>99m</sup>Tc and <sup>201</sup>Tl are now the most widely used myocardial

perfusion techniques for assessment of CAD. Concordance between MCE and SPECT has been demonstrated in many studies during rest or stress (Table 7).<sup>46–54</sup> A meta-analysis of eight studies comparing the sensitivity and specificity of MCE with those of SPECT/dobutamine stress echocardiography for the detection of CAD showed equivalent results.<sup>55</sup> In a recently concluded, first multicentre, international phase III trial comprising of 662 patients and with all images being read off-site by independent readers, MCE was found to be non-inferior to SPECT for the detection of CAD (Figure 1).<sup>56</sup> Similar trial with SonoVue (PHOENIX) is under way. Taken as an aggregate of published studies, the sensitivity and specificity of MCE for the detection of CAD is 83 and 80%, respectively (Table 8). However, it needs to be emphasized that training and expertise are required to achieve such results.<sup>57</sup>

Myocardial contrast echocardiography also provides incremental prognostic value over and above wall motion assessment in patients with stable CAD during dobutamine stress echocardiography.<sup>58</sup> Patients with normal perfusion have a better outcome than patients with normal wall motion, which underscores the value of incorporating MCE in stress echocardiography.

### Detection of acute coronary syndrome

The current diagnosis of ACS relies on clinical history, electrocardiography, and cardiac markers of necrosis. It has been shown that these parameters alone could detect ~30% of ACS when the patient presents in the emergency department.<sup>59</sup> In a large multicentre study, performance of MCE improved the detection of ACS over and above clinical, ECG, and biochemical markers at the time of presentation with chest pain and was equivalent to SPECT for risk stratification of these patients.<sup>60</sup> However, MCE is the only technique that allows immediate simultaneous assessment at the bedside of wall motion and perfusion and, in this regard, it offers a unique role in the diagnosis

**Table 7** Concordance of myocardial contrast echocardiography and single-photon emission computed tomography for detection of significant coronary artery stenosis in patients with suspected coronary artery disease

Study	Patients (n)	Imaging mode	Percentage concordance (kappa)		
			Patient basis	Territory basis	Segment basis
Kaul <i>et al.</i> <sup>46</sup>	30	THI	86 (0.71)	90 (0.77)	92 (0.99)
Heinle <i>et al.</i> <sup>47</sup>	123	HPD	81 (0.60)	76 (UN)	70 (0.32)
Shimoni <i>et al.</i> <sup>48</sup>	101	All	76 (0.50)	76–89 (UN)	92 (0.32)
Wei <i>et al.</i> , 2003 <sup>49</sup>	54	HPD	84 (0.63)	65 (0.41)	UN
Rocchi <i>et al.</i> <sup>50</sup>	25	HPD	84 (0.67)	92 (0.81)	UN
Olszowska <i>et al.</i> <sup>51</sup>	44	HPD	UN	73–91 (0.4–0.8)	89 (0.81)
Senior <i>et al.</i> <sup>52</sup>	55	IPI	UN	70 (0.37)	UN
Xie <i>et al.</i> <sup>53</sup>	36	RTI	75 (0.50)	85 (0.61)	UN
Korosoglou <i>et al.</i> <sup>54</sup>	120	PPI	UN	83 (0.65)	86 (0.65)
Total	(T)588				
Overall mean [95% CI]			81 [76.4–85.6]	81 [74.9–86.5]	86 [76.6–95]

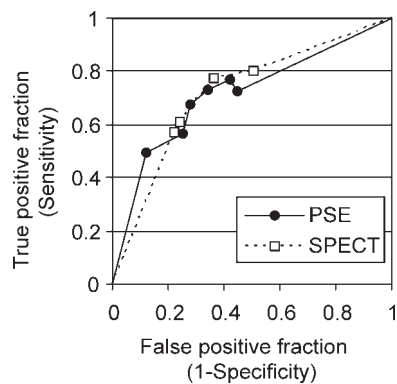
Values are expressed as concordance and agreement (kappa).

All, accelerated intermittent imaging; HPD, harmonic power Doppler; IPI, intermittent pulse inversion; PPI, power pulse inversion; RTI, real-time imaging; SPECT, single-photon-emission computed tomography; THI, triggered harmonic imaging; UN, unknown.

Adapted from Bhatia and Senior.<sup>104</sup>



of ACS. Studies have also reported high sensitivities with MCE to detect ACS compared with standard echocardiography and SPECT.<sup>61,62</sup> In a recent study of over 1000 patients, assessment of resting perfusion and function with MCE has been shown to be a powerful predictor of outcome, over and above clinical ECG and troponin assessment of patients presenting to emergency department with suspected CAD.<sup>63</sup> Patients who demonstrated normal function and perfusion at rest demonstrated excellent outcome.<sup>64</sup> Moreover, stress MCE may be used to safely assess prognosis in patients with significant cardiac risk factors presenting with chest pain, but a negative 12-h troponin and non-diagnostic ECG. In these patients, a negative stress MCE result predicted an excellent prognosis.<sup>65</sup>



**Figure 1** Multi-reader receiver operating characteristics. Values for each blinded reader from RAMP-1 and -2 trials. Modality-specific curves were extrapolated to the theoretical minimum and maximum values. AUCs were 0.72 for both PSE and SPECT.

## Detection of myocardial viability

Microvascular integrity is a pre-requisite for the sustenance of myocardial viability in dysfunctional segments.<sup>66</sup> Peak contrast intensity, a measure of capillary blood volume correlates with microvascular density and capillary area, and is inversely related to the collagen content.<sup>67</sup> Experimental models have established that contrast defect size assessed 10–15 s after contrast administration, corresponded to infarct size.<sup>68,69</sup> In humans, contrast defect intensity and degree of reduction of resting MBF after intravenous contrast administration predicted transmural extent of necrosis assessed by late gadolinium CMR imaging.<sup>70,71</sup> The ability of MCE to predict functional recovery is comparable with that of cardiac MRI.<sup>70</sup> Because contractile response with dobutamine depends not only on microvascular integrity (hence conservation of contractile protein) but also on MBF reserve, dobutamine stress echocardiography may be less sensitive than techniques that assess microvasculature directly (MCE) for the detection of hibernating myocardium.<sup>71,72</sup> Therefore, MCE may be particularly useful in further evaluation of myocardial viability in dobutamine non-responsive myocardium.<sup>73</sup> At least two studies indicated that MCE has superior sensitivity and equivalent specificity compared with dobutamine echocardiography and has equivalent sensitivity and superior specificity compared with SPECT imaging for the detection of hibernating myocardium.<sup>72,74</sup> Tables 9–11 summarizes the accuracy of MCE for the prediction of myocardial viability. Recent studies have also shown that among all the clinical, ECG, and angiographic parameters of reperfusion after AMI, contrast perfusion is the only independent predictor of reperfusion.<sup>75–77</sup> With accumulating evidence of its prognostic value for the detection of myocardial viability over and above clinical

**Table 8** Accuracy of myocardial contrast echocardiography for the detection of coronary artery disease

Study	Patients undergoing coronary angiography	CAD present	MCE sensitivity	MCE specificity
Chiou <i>et al.</i> <sup>105</sup>	132	85	81	77
Cwaig <i>et al.</i> <sup>106</sup>	45	32	87	66
Elhendy <i>et al.</i> <sup>107</sup>	170	127	91	51
Heinle <i>et al.</i> <sup>47</sup>	15	12	75	67
Jeetley <i>et al.</i> <sup>108</sup>	123	96	84	56
Karavidas <i>et al.</i> <sup>109</sup>	47	11	91	92
Korosoglou <i>et al.</i> <sup>54</sup>	89	62	83	72
Lin <i>et al.</i> <sup>110</sup>	40	25	84	93
Malm <i>et al.</i> <sup>111</sup>	43	33	77	72
Moir <i>et al.</i> <sup>26</sup>	90	48	93	65
Olszowska <i>et al.</i> <sup>51</sup>	44	44	97	93
Peltier <i>et al.</i> <sup>83</sup>	35	22	Qualitative 85 Quantitative 97	Qualitative 79 Quantitative 79–82
Rocchi <i>et al.</i> <sup>50</sup>	12	12	89	100
Senior <i>et al.</i> <sup>52</sup>	55	43	86	88
Senior <i>et al.</i> <sup>85</sup>	52	22	82	97
Shimoni <i>et al.</i> <sup>48</sup>	44	28	75	100
Tsutsui <i>et al.</i> <sup>93</sup>	16	13	RT imaging 64TR imaging 41	RT imaging 92 TR imaging 96
Winter <i>et al.</i> <sup>112</sup>	36	35	81	67
Hayat <i>et al.</i> <sup>86</sup>	63	25	92	95
Aggeli C <i>et al.</i> <sup>41</sup>	532	413	92	61
Total	1683	1345		
Mean [95% CI]			83 [78–88]	80 [73–87]

**Table 9** Accuracy of resting intravenous myocardial contrast echocardiography for the prediction of myocardial viability

Authors	Type of imaging	No. of patients (n = 736)	MCE perfusion	
			Sensitivity (%)	Specificity (%)
Sbano <i>et al.</i> <sup>113</sup>	High MI	50	95	52
Senior <i>et al.</i> <sup>73</sup>	High MI	96	62	83
Aggeli <i>et al.</i> <sup>114</sup>	High MI	34	88	61
Hillis <i>et al.</i> <sup>115</sup>	Low MI	33	86	44
Main <i>et al.</i> <sup>116</sup>	Low MI	46	69	85
Swinburn <i>et al.</i> <sup>117</sup>	Low MI	19	68	88
Hillis <i>et al.</i> <sup>118</sup>	High MI	35	80	67
Lepper <i>et al.</i> <sup>119</sup>	High MI	35	94	87
Janardhanan <i>et al.</i> <sup>70</sup>	Low MI	42	82	83
Hickman <i>et al.</i> <sup>120</sup>	Low MI	56	83	78
Greaves <i>et al.</i> <sup>75</sup>	Low MI	15	88	74
Janardhanan <i>et al.</i> <sup>121</sup>	Low MI	50	92	75
Main <i>et al.</i> <sup>122</sup>	Low MI	34	77	83
Shimoni <i>et al.</i> <sup>74</sup>	High MI	18	90	63
Hickman <i>et al.</i> <sup>72</sup>	Low MI	23	87	67
Agati <i>et al.</i> <sup>123</sup>	High MI	23	100	90
Huang <i>et al.</i> <sup>124</sup>	Low MI	34	83	82
Bolognese <i>et al.</i> <sup>76</sup>	High MI	30	96	18
Abe <i>et al.</i> <sup>125</sup>	High MI	31	98	32
Kousouglou <sup>126</sup>	Low MI	32	81	88
Mean			85	70

MCE, myocardial contrast echocardiography.

**Table 10** Interpretation of resting contrast echo studies

Wall motion	Myocardial contrast	Diagnostic confidence
Normal	Normal	High
Abnormal	Abnormal	High
Abnormal	Normal	Stunning, hibernation
Normal	Abnormal	Artefact

**Table 11** Interpretation of stress contrast studies

Wall motion	Myocardial contrast	Diagnostic confidence
Normal	Normal	High
New WMA	Perfusion defect	High perfusion defect often depicts extent of ischaemia better
New WMA	Normal	May be artefact, but if in centre of plane cardiomyopathy
Normal	Perfusion defect	Ischaemia

markers and LVEF, MCE is evolving as a useful bedside technique that may be used as first line investigation for the assessment of myocardial viability.<sup>77-80</sup> Algorithms for the use of MCE after AMI are shown in *Figure 2A* and *B*.<sup>81</sup>

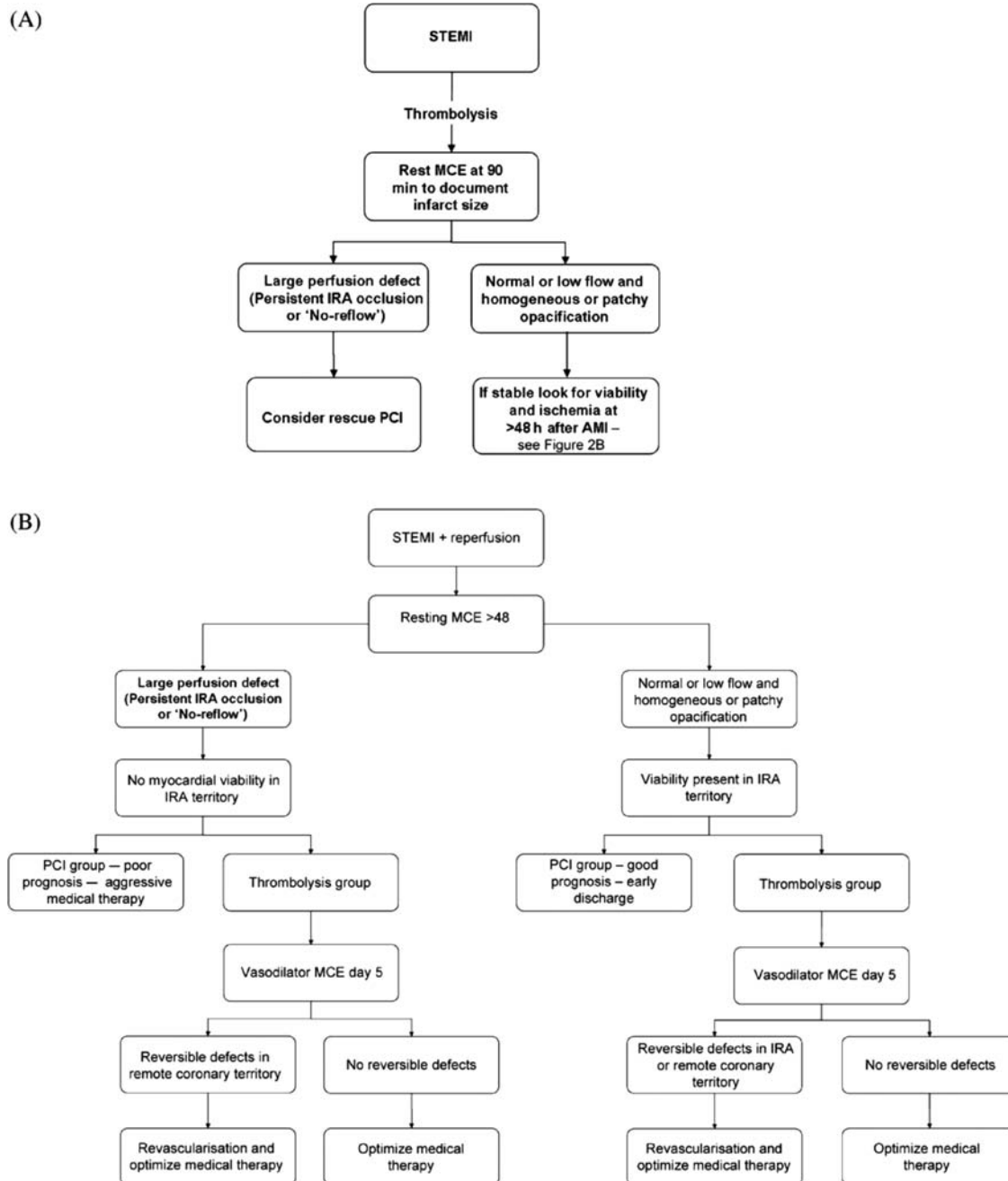
### Assessment of coronary flow reserve by myocardial contrast echocardiography

The first experimental study by Wei *et al.*<sup>45</sup> established quantitative evaluation of MBF using MCE. In a subsequent

clinical study by the same group, they showed that assessment of MBF during hyperaemia provided an accurate assessment of coronary flow reserve.<sup>82</sup> This was subsequently replicated by other authors.<sup>83</sup> Indeed, Vogel *et al.*<sup>84</sup> demonstrated that MBF assessed by MCE at rest and during hyperaemia closely correlated with MBF assessed by positron emission tomography. Further studies in various cardiovascular disease conditions showed that coronary flow reserve assessed by MCE can accurately assess both the presence and severity of flow-limiting CAD.<sup>85-88</sup> This assessment can be performed using both low and high MI imaging techniques. The myocardium is first cleared of microbubbles during high MI imaging and subsequent replenishment is assessed in time (*Figure 3*). Myocardial blood flow which is the product of peak contrast intensity and myocardial flow velocity is obtained. It is obtained in each of the myocardial segments in the apical views (preferably avoiding the basal segments—see below). The MBF obtained in each segment can then be collapsed into the three vascular territories. The process is repeated during stress myocardial imaging preferably vasodilator stress. The ratio of the peak MBF and that of resting flow indicates coronary flow reserve. The ratio of peak myocardial blood velocity ( $\beta/\text{rest } \beta$ ) also provides a robust estimate of coronary flow reserve.<sup>82</sup>

### Limitations of myocardial contrast echocardiography

Myocardial contrast echocardiography, like all other techniques, requires training and understanding of the technology. The signature of MCE is the result of interaction between the microbubbles and ultrasound power. Thus, variation in concentration of microbubbles with each administration may influence the contrast intensity. Ultrasound power is not uniform in the field of view and this may



Hayat and Senior<sup>81</sup>

**Figure 2** (A) Schematic diagram for the proposed role of myocardial contrast echocardiography in assessment of patients in the acute phase of STEMI. (B) Schematic diagram for the proposed role of myocardial contrast echocardiography in assessment of patients with recent STEMI following reperfusion Hayat and Senior.<sup>81</sup>

affect the estimation of myocardial blood volume and velocity. Because ultrasound power is weakest in the far field, contrast intensity may be falsely reduced at the bases of the heart. Similarly, as the power of ultrasound is the strongest in the near-field, and apical destruction of contrast may result in false perfusion defects. However, recent advancement in technology and understanding of microbubble and ultrasound interaction has improved interpretation significantly. In a recently concluded multicentre trial involving 27 centres in USA and Europe, diagnostic images could be obtained in 99% of patients. The reproducibility of multiple

MCE readers was non-inferior and similar to that of SPECT readers.<sup>56</sup>

## Protocols for myocardial contrast echocardiography

### Exercise stress protocol

The protocols are the same as for native stress echocardiography.<sup>89</sup> Recordings are performed at rest according to the protocol for rest echocardiography (Figures 4 and 5).

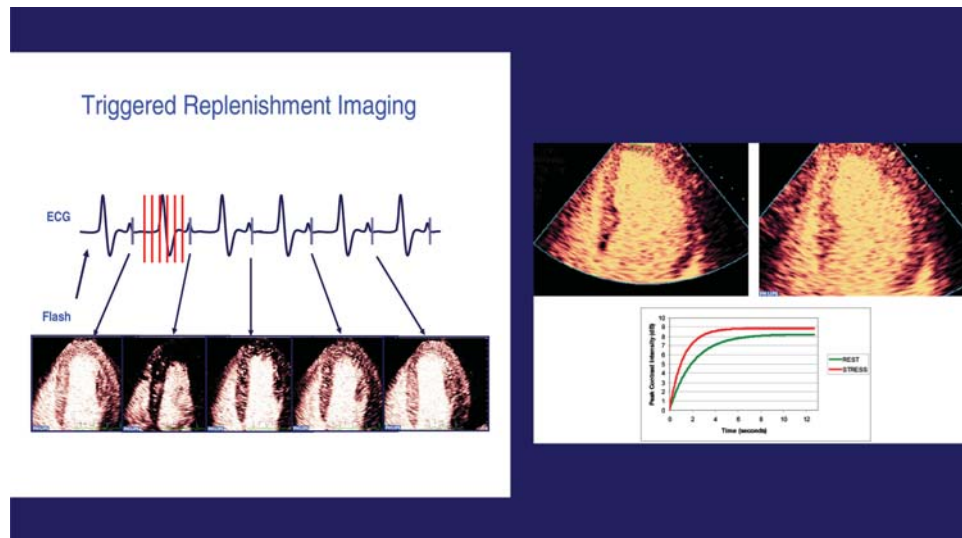


Figure 3 Quantification of myocardial blood flow by myocardial contrast echocardiography.

Further image acquisition is performed immediately after treadmill exercise, upright or supine bicycle ergometry. Because ischaemia-induced wall motion abnormalities may resolve quickly, post-treadmill exercise imaging should be accomplished within 60–90 s of termination of exercise. Therefore, it is necessary to inject the bolus (if only wall motion is assessed) or start the infusion (ideal for assessing perfusion) of contrast before the patient terminates the exercise. After application of the contrast agent, the patient should be asked to continue the exercise for at least 20 s, before laying down for image acquisition.

### Dobutamine stress echocardiography

The protocol for native dobutamine stress echocardiography is described elsewhere except apical views are acquired first (Figure 6).<sup>89</sup> Resting image settings should be optimized and resting contrast echocardiogram views should be obtained according to the criteria described previously. The same views are acquired at an intermediate stage (70% of the maximum age predicted heart rate) and at peak stress (85% of the maximum age predicted heart rate). Contrast can be administered as a bolus or as an infusion, as described previously. If the SonoVue-infusion pump or Luminity drip is used, infusion is needed only while acquiring the images. Prior to acquisition of the peak stress loops, the contrast infusion is started and the dobutamine infusion is stopped. Within 30 s, there is sufficient contrast enhancement and the peak contrast images are acquired in the apical views (and parasternal views if of sufficient quality). Image acquisition at stress is not different from acquisition at rest except when using triggered imaging. A 1:1 trigger interval should be used at peak stress whereas at rest 1:4 is useful. Adjustment of the time delay of the trigger may be necessary at peak stress to allow for the increased heart rate.

### Vasodilator stress

#### Vasodilator stress is the best stress modality for perfusion imaging

An amount of 0.56 mg/kg of dipyridamole (half-life 30 min) is administered intravenously over 4 min; contrast

echocardiograms are acquired at rest (before infusion) and 2 min after completion of infusion. The same infusion line is used to administer the contrast agent and the vasodilator. Alternatively, an infusion of adenosine 140  $\mu\text{g}/\text{kg}/\text{min}$  (half-life 4–10 s) can be used. The contrast echocardiograms are acquired prior to infusion and again during the infusion at 3 min. Usually, all the three apical views  $\pm$  available parasternal views can be acquired within the subsequent 3 min, resulting in a total adenosine infusion time of 6 min (Figure 7). For both vasodilators, a three-way tap or small bore Y connector is useful to connect the vasodilator infusion lines and contrast infusion pump.

### Myocardial contrast echocardiography for myocardial viability

Rest contrast images are acquired as described previously. However, when real-time imaging protocol is used, it is important to acquire at least 15 sc cycle post-flash for optimal assessment. It has been shown that both the presence of homogenous contrast uptake and, alternatively, the absence of contrast uptake are very accurate indicators of the presence or absence of myocardial viability, respectively. It is, however, important to exclude apical and basal artefacts before concluding that there is absent contrast uptake. High MI imaging should also include imaging up to 15 s intermittent image acquisition. The transmit focus should be moved towards the apex to confirm an apical perfusion defect when suspected. A thin and scarred (bright) myocardium of <5 mm in size indicates non-viable tissue and it is unnecessary to assess perfusion in these segments.

### Analyses

#### Left ventricular function and regional wall motion

Visual analysis of LV function is performed in all patients according to EAE/ASE guidelines for non-contrast imaging.<sup>89</sup> Myocardial contrast and, particularly, the enhancement of the epicardial vessels helps in judging wall thickening as well as inward motion of the myocardium. Contrast images are ideal for measuring LV volumes and LVEF. The post-flash (destruction) images provide the best

## 2.2 Protocol 1 (low power, real-time) — steps

- 1: standard 2D (tissue harmonic) imaging to adjust scanplanes.
- 2: activate preset *Contrast preset 1 (low power, real-time)*.
- 3: adjust focus (mitral valve level) and gain to achieve some mild background noise (on some scanners, it is only one gain control, whereas on other there different controls for time gain compensation and lateral gain), adjust sector width to obtain frame rate >25 Hz.
- 4: inject contrast bolus (0.3 mL Optison, 0.3 mL Luminity or 0.3 mL SonoVue) or infuse contrast agent 0.8–0.9 mL/min Sonovue or 1 drop/s Luminity.
- 5A: Image acquisition for *bolus injection* (digital loops preferable, back-up on tape) usually it takes at least 30 s after the injection of contrast to opacify the LV before acquiring images check whether LV and myocardial opacification is adequate and that no attenuation is present  
4CV, 2CV, 3CV (SAX and LAX may be omitted as they cause attenuation)  
1 beat loops in each view.
- 5B: Image acquisition for *contrast infusion* (digital loops preferable, back up on tape):  
usually it takes at least 30 s after start of infusion to opacify the LV before acquiring images check whether LV and myocardial opacification is adequate and reduce infusion rate if attenuation is present  
4CV, 2CV, 3CV (SAX and LAX may be omitted to save contrast agent)  
1 beat loops in each view  
flash replenishment technique when infusing contrast  
(15 beat loop, high power flash after 2 cardiac cycles )  
  
The setting of the flash has to be adjusted during rest, the flash should clear the contrast from the myocardium with visible destruction (=reduction in intensity in the LV cavity), start with 7 frames duration and MI 0.9)  
Triggered low power imaging: use 1:1 trigger, trigger point at endsystole, flash replenishment technique like for real-time imaging and record additional single beat loops in real-time to record wall motion

**Figure 4** Protocol for myocardial contrast echocardiography. Protocol 1.

contrast between myocardium and the LV cavity. Manual tracing on still frames to obtain LV volumes and ejection fraction is easy and quick. Therefore, in every contrast study, these measurements should be obtained. The tools for automatic assessment of LV borders (such as colour kinesis), as well as 3D echocardiographic volumetric assessments with contrast are currently being investigated in clinical trials and may be useful clinical tools in the future.<sup>90,91</sup>

### Myocardial perfusion

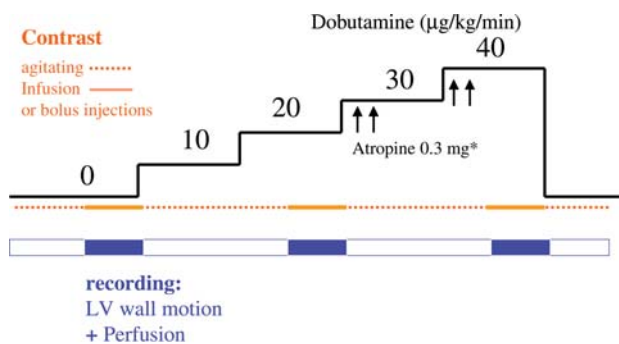
Although there is growing evidence of the usefulness of quantitative analysis,<sup>92</sup> myocardial contrast signals are currently judged using visual assessment.

Normal myocardial perfusion is displayed by homogeneous contrast enhancement at rest 5 s after flash (Low MI imaging) or high MI imaging and a quick replenishment at stress (within 2 s).

### 2.3 Protocol 2 (high power, triggered imaging) — steps

- 1: standard 2D (tissue harmonic) imaging to adjust scanplanes
- 2: activate preset *Contrast preset 2 (high power, triggered imaging) second harmonic, ultraharmonic, pulse inversion or harmonic power Doppler (Angio)*
- 3: adjust focus (mitral valve level) and gain to achieve some mild background noise (on some scanners it is only one gain control on other there different controls for time gain compensation and lateral gain)
- 4: adjust trigger (=select the R wave delay for frame acquisition)  
double trigger (consecutive imaging and destruction frame):  
helps to control whether wall motion artefacts are present  
and the contrast agent has been completely destroyed by the imaging frame  
trigger point : end-systolic trigger work, avoid upsloping part of T wave!  
trigger interval: every fourth cardiac cycle for visual analysis
- 5: infuse contrast agent (0.9 mL/min SonoVue or 1 drop/s Luminity)  
*for triggered imaging infusion of contrast is recommended*
- 6: Image acquisition for *contrast infusion* (digital loops preferable, back up on tape):  
usually it takes at least 30 s to opacify the myocardium  
before acquiring images check whether LV and myocardial opacification is adequate in 4CV (decrease infusion speed in case of attenuation, increase infusion speed if a normally/hypokinetic contracting mid or apical segment is not opacified)  
4CV, 2CV, 3CV (SAX and LAX may be omitted to avoid attenuation)

Figure 5 Protocol for myocardial contrast echocardiography. Protocol 2.



\*Atropine (0.3 mg, maximum 1.2 mg) is given, if there is no adequate increase in heart rate

Figure 6 Dobutamine stress contrast protocol.

### Perfusion defect by myocardial contrast echocardiography

A visually evident contrast defect is considered present when there is a relative decrease in contrast enhancement in one region compared with other adjacent regions that

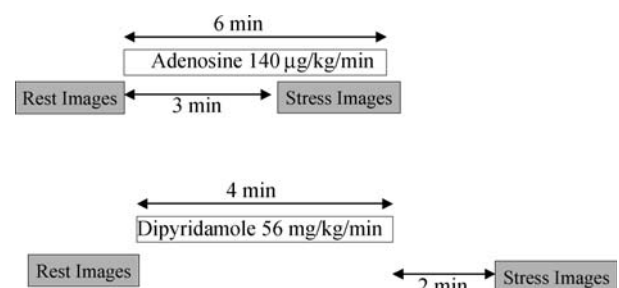


Figure 7 Vasodilator protocol.

have the same or worse imaging conditions. The diagnostic confidence of an observed perfusion defect increases when two contiguous segments fail to exhibit contrast enhancement. A contrast defect is usually seen first in the subendocardium and does not extend over the full thickness of the myocardium. The specificity for the detection of a perfusion defect is decreased in the absence of at least some contrast signal in the epicardium; full thickness defects in which both endocardium and epicardium are absent are more likely to

be due to artefact such as attenuation or rib shadowing. Basal lateral and anterior walls quite often cannot be assessed because of these limitations. However, there is usually enough adequate information in other segments in the LAD or RCX perfusion territories to permit the assessment of adequacy of perfusion by coronary artery territory.

#### Fixed vs. reversible perfusion defect

Fixed perfusion defects are visible at rest and stress. Reversible defects are best seen early after the flash (during the first 2 cardiac cycles using real-time imaging) or with low trigger rate (1:1 using high power triggered imaging). Reversible defects suggestive of CAD are characterized by delayed subendocardial replenishment and subendocardial hypoenhancement. With longer replenishment time (low MI imaging) or increased trigger intervals (high MI imaging), reversible defects often decrease in size or fill in.

When assessing for potential perfusion defects, it is crucial to avoid either oversaturation with contrast, or alternatively, inadequate concentration of contrast. Subtle subendocardial defects may be obscured by excess contrast. These may be revealed by a reduction in contrast infusion rate or further bubble destruction with additional intermittent high power frames. On the other hand, inadequate contrast concentration will obviate the detection of normally perfused and relatively underperfused regions.

#### Integrating wall motion findings and judgment of perfusion

##### During rest echocardiography (Table 10)

This may be particularly useful when the assessment of LV wall motion is difficult or dubious at rest. Probably, the most important situation where perfusion imaging makes a difference is in akinetic areas (Table 7). Before one tries to assess myocardial contrast enhancement, it is important to look at myocardial thickness that often can be seen very well during infusion of contrast. When analysing loops obtained with real-time imaging, judgement of wall motion and myocardial perfusion is often combined. A subendocardial perfusion defect makes a wall motion abnormality much clearer and vice versa. Thus, assessment of myocardial contrast often helps by increasing the diagnostic confidence of dubious wall motion analysis. In a resting study, a perfusion defect can be due to ischaemia with a flow limiting coronary stenosis at rest, a scar, or an artefact. Artefacts are most likely to occur in the basal lateral and anterior walls and can easily be detected by the typical criteria of attenuation and shadowing, in the presence of normal myocardial wall thickening. Other discrepant findings between wall motion and myocardial contrast enhancement occur with stunning and hibernation. Both conditions can be suspected when reduced wall motion and good contrast enhancement are found in a resting perfusion study.

##### During stress echocardiography (Table 11)

Concordant findings in wall motion and perfusion increase our confidence when assessing a dubious wall motion abnormality. For instance, when asked for the significance of an angiographically determined coronary stenosis, normal wall motion and perfusion in the territory supplied by this vessel should negate the need for coronary

intervention. Combined assessment of wall motion and perfusion can also help to increase the diagnostic confidence of abnormal findings. A new wall motion abnormality accompanied by a perfusion defect suggests flow-limiting CAD. A new wall motion abnormality without a corresponding perfusion defect may suggest cardiomyopathy.

#### Training and accreditation

Both physicians and cardiac sonographers must have acquired basic echocardiography training and preferably accredited in echocardiography before using contrast agents. Those planning to use contrast agents during stress echocardiography must be accredited or at least must have undergone equivalent training in stress echocardiography. Beyond these trainings in rest and stress echocardiography, the use of contrast agents requires a level of experience and performance, initially under guidance or supervision. Physicians, sonographers, and nurses alike should be competent in the administration of contrast agents, should be aware of the indications and contraindications, and should be able to manage adverse events. It is encouraged that personnel involved in contrast use should attend courses, etc. to learn and familiarize themselves with the use of contrast, performance, and interpretation of contrast-enhanced images. This is particularly important if the echo team is contemplating using contrast for assessment of perfusion also.<sup>127,128</sup> The echo team should seek guidance from the local echocardiography society of institutional director to determine ways to set up myocardial perfusion programme. It cannot be emphasized more that experience with contrast agent for LVO is a prerequisite for moving on to assess perfusion and function with contrast agents.

#### Conclusions

Contrast echocardiography significantly improves the image quality during rest and stress echocardiography and at the same time provides additional information on myocardial perfusion. Contrast echocardiography reduces the need for additional, costly, and more hazardous tests and, importantly, spares the patient further invasive investigations. Thus, contrast echocardiography provides a safe and comprehensive assessment of cardiac structure, function, perfusion, and coronary flow reserve at the bedside.

**Conflict of interest:** R.S. received research support from Bracco, Acusphere. M.M. has received research support from Bracco, Acusphere, Philips, GE, Siemens; Speaker's Bureau: Philips, Siemens. P.N. has received research grants from Bracco and Medtronic. H.B. acts as a consultant for Lantheaus, Bracco, POINT, Acusphere and has research grants from Phillips, Sonosite, Siemens, Toshiba.

#### References

1. Olszewski R, Timperley J, Cezary S, Monaghan M, Nihoyannopoulos P, Senior R *et al.* The clinical applications of contrast echocardiography. *Eur J Echocardiogr* 2007;8:S13-S23.
2. Mulvagh SL, Rakowski H, Vannan MA, Abdelmoneim SS, Becher H, Bierig M *et al.* ASE consensus statement on the clinical applications of ultrasonic contrast agents in echocardiography. *J Am Soc Echocardiogr* 2008;21:1179-1201.
3. Thanigaraj S, Nease RF, Schechtman KB *et al.* Use of contrast for image enhancement during stress echocardiography is cost-effective and reduces additional diagnostic testing. *Am J Cardiol* 2001;87:1430-2.

4. Main ML, Grayburn PA. Clinical applications of transpulmonary contrast echocardiography. *Am Heart J* 1999;137:144–53.
5. McCulloch M, Gresser C, Moos S, Odabashian J, Jasper S, Bednarz J *et al*. Ultrasound contrast physics: a series on contrast echocardiography. *J Am Soc Echocardiogr* 2000;13:959–67.
6. EMEA Scientific Discussion. *SonoVue, European Public Assessment Report*. 2004; <http://www.emea.europa.eu/humandocs/Humans/EPAR/SonoVue/SonoVue.htm> (Accessed on 17 September).
7. GE Healthcare. *OPTISON Prescribing Information*. 2008; <http://www.amershamhealth-us.com/optison/> (Accessed on 17 September).
8. *Luminitry Summary of Product Characteristics*. 2008
9. Senior R, Kaul S, Soman P, Lahiri A. Power doppler harmonic imaging: a feasibility study of a new technique for the assessment of myocardial perfusion. *Am Heart J* 2000;139:245–51.
10. Kuersten B, Murthy TH, Li P, Liu Z, Locricchio E, Baisch C *et al*. Ultraharmonic myocardial contrast imaging: in vivo experimental and clinical data from a novel technique. *J Am Soc Echocardiogr* 2001;14:910–6.
11. Sieswerda GT, Yang L, Boo MB *et al*. Real-time perfusion imaging: a new echocardiographic technique for simultaneous evaluation of myocardial perfusion and contraction. *Echocardiography* 2003;20:545–55.
12. Bristol-Myers Squibb. *Data on file, Definity Common Technical Document*. Module 2: 2.7.3 Summary of Clinical Efficacy.
13. Hundley WG, Kizilbash AM, Afridi I, Franco F, Peshock RM, Grayburn PA. Administration of an intravenous perfluorocarbon contrast agent improves echocardiographic determination of left ventricular volumes and ejection fraction: comparison with cine magnetic resonance imaging. *J Am Coll Cardiol* 1998;32:1426–32.
14. Reilly JP, Tunick PA, Timmermans RJ, Stein B, Rosenzweig BP, Kronzon I. Contrast echocardiography clarifies uninterpretable wall motion in intensive care unit patients. *J Am Coll Cardiol* 2000;35:485–90.
15. Nahar T, Croft L, Shapiro R, Fruchtman S, Diamond J, Henzlova M *et al*. Comparison of four echocardiographic techniques for measuring left ventricular ejection fraction. *Am J Cardiol* 2000;86:1358–62.
16. Yu EH, Sloggett CE, Iwanochko RM, Rakowski H, Siu SC. Feasibility and accuracy of left ventricular volumes and ejection fraction determination by fundamental, tissue harmonic, and intravenous contrast imaging in difficult-to-image patients. *J Am Soc Echocardiogr* 2000;13:216–24.
17. Yong Y, Wu D, Fernandes V, Kopelen HA, Shimoni S, Nagueh SF *et al*. Diagnostic accuracy and cost-effectiveness of contrast echocardiography on evaluation of cardiac function in technically very difficult patients in the intensive care unit. *Am J Cardiol* 2002;89:711–8.
18. Malm S, Frigstad S, Sagberg E, Larsson H, Skjaerpe T. Accurate and reproducible measurement of left ventricular volume and ejection fraction by contrast echocardiography: a comparison with magnetic resonance imaging. *J Am Coll Cardiol* 2004;44:1030–5.
19. Hoffmann R, von Bardeleben S, ten Cate F, Borges AC, Kasprzak J, Firsckhe C *et al*. Assessment of systolic left ventricular function: a multi-centre comparison of cineventriculography, cardiac magnetic resonance imaging, unenhanced and contrast-enhanced echocardiography. *Eur Heart J* 2005;26:607–16.
20. Lim TK, Burden L, Janardhanan R, Ping C, Moon J, Pennell D *et al*. Improved accuracy of low-power contrast echocardiography for the assessment of left ventricular remodeling compared with unenhanced harmonic echocardiography after acute myocardial infarction: comparison with cardiovascular magnetic resonance imaging. *J Am Soc Echocardiogr* 2005;18:1203–7.
21. Weiss RJ, Lieux TR, Ahmad M, Shirani J. An open-label, randomised, multi-centre trial to examine the predictive value of Definity contrast stress echocardiography on patient outcomes. *J Am Soc Echocardiogr* 2005;18:502–14.
22. Shaw LJ, Monaghan MJ, Nihoyannopoulos P. Clinical and economic outcomes assessment with myocardial contrast echocardiography. *Heart* 1999;82:16–21.
23. Dolan MS, Riad K, El-Shafei A, Puri S, Tamirisa K, Bierig M *et al*. Effect of intravenous contrast for left ventricular opacification and border definition on sensitivity and specificity of dobutamine stress echocardiography compared with coronary angiography in technically difficult patients. *Am Heart J* 2001;142:908–15.
24. Shimoni S, Zoghbi WA, Xie F, Kricsfeld D, Iskander S, Gobar L *et al*. Real-time assessment of myocardial perfusion and wall motion during bicycle and treadmill exercise echocardiography: comparison with single photon emission computed tomography. *J Am Coll Cardiol* 2001;37:741–7.
25. Rainbird AJ, Mulvagh S, Oh JK, McCully RB, Klarich KW, Shub C *et al*. Contrast dobutamine stress echocardiography clinical practice assessment in 300 consecutive patients. *J Am Soc Echocardiogr* 2001;14:375–8.
26. Moir S, Haluska BA, Jenkins C, Fathi R, Marwick TH. Incremental benefit of myocardial contrast to combined dipyridamole-exercise stress echocardiography for the assessment of coronary artery disease. *Circulation* 2004;110:1108–13.
27. Calachanis M, Evdoris C, Nihoyannopoulos P. Improved diagnostic accuracy of dobutamine stress echocardiography with Echogen. *Cardiovasc Imag* 1999;11:123.
28. Plana JC, Mikati IA, Dokainish H, Lakkis N, Abukhalil J, Davis R *et al*. A randomized cross-over study for evaluation of the effect of image optimization with contrast on the diagnostic accuracy of dobutamine echocardiography in coronary artery disease. *J Am Coll Cardiol Cardiac Imaging* 2008;1:145–52.
29. Jeetley P, Burden L, Stoykova B, Senior R. Clinical and economic impact of stress echocardiography compared to exercise electrocardiography in patients with suspected acute coronary syndrome but negative troponin: a prospective randomised controlled study. *Eur Heart J* 2007;28:204–11.
30. Thanigaraj S, Nease RF Jr, Schechtman KB, Wade RL, Loslo S, Pérez JE. Use of contrast for image enhancement during stress echocardiography is cost-effective and reduces additional diagnostic testing. *Am J Cardiol* 2001;87:1430–2.
31. Vlassak I, Rubin DN, Odabashian JA, Garcia MJ, King LM, Lin SS *et al*. Contrast and harmonic imaging improves accuracy and efficiency of novice readers for dobutamine stress echocardiography. *Echocardiography* 2002;19:483–8.
32. Soman P, Swinburn J, Callister M, Stephens NG, Senior R. Apical hypertrophic Cardiomyopathy: bedside diagnosis by intravenous contrast echocardiography. *J Am Soc Echocardiogr* 2001;14:311–3.
33. Thanigaraj S, Schechtman KB, Perez JE. Improved echocardiographic delineation of left ventricular thrombus with the use of intravenous second-generation contrast image enhancement. *J Am Soc Echocardiogr* 1999;12:1022–6.
34. Koo BK, Choi D, Ha JW, Kang SM, Chung N, Cho SY. Isolated noncompaction of the ventricular myocardium: contrast echocardiographic findings and review of the literature. *Echocardiography* 2002;19:153–6.
35. Mittle S, Makaryus AN, Mangion J. Role of contrast echocardiography in the assessment of myocardial rupture. *Echocardiography* 2003;20:77–81.
36. Kusnetzky LL, Khalid A, Khumri TM, Moe TG, Jones PG, Main ML. Acute mortality in hospitalized patients undergoing echocardiography with and without an ultrasound contrast agent. *J Am Coll Cardiol* 2008;51:1704–6.
37. Timperley J, Mitchell AR, Thibault H, Mirza IH, Becher H. Safety of contrast dobutamine stress echocardiography: a single center experience. *J Am Soc Echocardiogr* 2005;18:163–7.
38. Anantharam B, Chahal N, Chelliah R, Ramzy I, Gani F, Senior R. Safety of contrast in stress echocardiography in stable patients and in patients with suspected acute coronary syndrome but negative 12 hour Troponin. *Am J Cardiol* 2009 (in press).
39. Tsutsui JM, Elhendy A, Xie F, O'Leary EL, McGrain AC, Porter TR. Safety of dobutamine stress real-time myocardial contrast echocardiography. *J Am Coll Cardiol* 2005;19:1235–42.
40. Aggeli C, Giannopoulos G, Roussakis G, Christoforatu E, Marinos G, Toli C *et al*. Safety of myocardial flash-contrast echocardiography in combination with dobutamine stress testing for detection of ischemia in 5250 studies. *Heart* 2008;94:1571–7.
41. Main ML, Goldman JH, Grayburn PA. Thinking outside the 'box'—the ultrasound contrast controversy. *J Am Coll Cardiol* 2007;18:2434–7.
42. Wei K, Mulvagh SL, Carson L, Davidoff R, Gabriel R, Grim RA *et al*. The safety of Definity and Optison for ultrasound image enhancement: a retrospective analysis of 78,383 administered contrast doses. *J Am Soc Echocardiogr* 2008;21:1202–6.
43. Kaul S, Jayaweera AR. Coronary and myocardial blood volumes: noninvasive tools to assess the coronary microcirculation. *Circulation* 1997;96:719–24.
44. Wei K, Jayaweera AR, Firoozan S, Linka A, Skyba DM, Kaul S. Basis for detection of stenosis using venous administration of microbubbles during myocardial contrast echocardiography: bolus or continuous infusion? *J Am Coll Cardiol* 1998;32:252–60.
45. Wei K, Jayaweera AR, Firoozan S, Linka A, Skyba DM, Kaul S. Quantification of myocardial blood flow with ultrasound-induced destruction of microbubbles administered as a constant venous infusion. *Circulation* 1998;97:473–83.



46. Kaul S, Senior R, Dittrich H, Raval U, Khattar R, Lahiri A. Detection of coronary artery disease with myocardial contrast echocardiography: comparison with <sup>99m</sup>Tc-sestamibi single-photon emission computed tomography. *Circulation* 1997;**96**:785-92.
47. Heinle SK, Noblin J, Goree-Best P, Mello A, Ravad G, Mull S et al. Assessment of myocardial perfusion by harmonic power Doppler imaging at rest and during adenosine stress: comparison with <sup>99m</sup>Tc-sestamibi SPECT imaging. *Circulation* 2000;**102**:55-60.
48. Shimoni S, Zoghbi WA, Xie F, Kricsfeld D, Iskander S, Gobar L et al. Real-time assessment of myocardial perfusion and wall motion during bicycle and treadmill exercise echocardiography: comparison with single photon emission computed tomography. *J Am Coll Cardiol* 2001;**37**:741-7.
49. Wei K, Crouse L, Weiss J, Villanueva F, Schiller NB, Naqvi TZ et al. Comparison of usefulness of dipyridamole stress myocardial contrast echocardiography to technetium-99m sestamibi single-photon emission computed tomography for detection of coronary artery disease (PB127 Multicenter Phase 2 Trial results). *Am J Cardiol* 2003;**91**:1293-8.
50. Rocchi G, Fallani F, Bracchetti G, Rapezzi C, Ferlito M, Levorato M et al. Non-invasive detection of coronary artery stenosis: a comparison among power-Doppler contrast echo, <sup>99</sup>Tc-Sestamibi SPECT and echo wall-motion analysis. *Coron Artery Dis* 2003;**14**:239-45.
51. Olszowska M, Kostkiewicz M, Tracz W, Przewlocki T. Assessment of myocardial perfusion in patients with coronary artery disease. Comparison of myocardial contrast echocardiography and <sup>99m</sup>Tc MIBI single photon emission computed tomography. *Int J Cardiol* 2003;**90**:49-55.
52. Senior R, Lepper W, Pasquet A, Chung G, Hoffman R, Vanoverschelde JL et al. Myocardial perfusion assessment in patients with medium probability of coronary artery disease and no prior myocardial infarction: comparison of myocardial contrast echocardiography with <sup>99m</sup>Tc single-photon emission computed tomography. *Am Heart J* 2004;**147**:1100-5.
53. Xie F, Tsutsui JM, McGrain AC, DeMaria A, Cotter B, Becher H et al. Comparison of dobutamine stress echocardiography with and without real-time perfusion imaging for detection of coronary artery disease. *Am J Cardiol* 2005;**96**:506-11.
54. Korosoglou G, Dubart AE, DaSilva KG Jr, Labadze N, Hardt S, Hansen A et al. Real-time myocardial perfusion imaging for pharmacologic stress testing: added value to single photon emission computed tomography. *Am Heart J* 2006;**151**:131-8.
55. Dijkmans PA, Senior R, Becher H, Porter TR, Wei K, Visser CA et al. Myocardial contrast echocardiography evolving as a clinically feasible technique for accurate, rapid, and safe assessment of myocardial perfusion: the evidence so far. *J Am Coll Cardiol* 2006;**48**:2168-77.
56. Senior R, Monaghan M, Main ML, Zamorano JL, Tiemann K, Agali L et al. Detection of coronary artery disease with perfusion stress echocardiography using a novel ultrasound imaging agent: two phase 3 inter-national trials in comparison with radionuclide perfusion imaging. *Eur J Echocardiogr* 2009;**10**:26-35.
57. Marwick TH, Brunken R, Meland N, Brochet E, Baer FM, Binder T et al. Accuracy and feasibility of contrast echocardiography for detection of perfusion defects in routine practice: Comparison with wall motion and Technetium-99, Sestamibi Single Photon Emission Computed Tomography. *J Am Coll Cardiol* 1998;**32**:1260-9.
58. Tsutsui JM, Elhendy A, Anderson JR, Xie F, McGrain AC, Porter TR. Prognostic value of dobutamine stress myocardial contrast perfusion echocardiography. *Circulation* 2005;**112**:1444-50.
59. Sabia P, Abbott RD, Afrookteh A, Keller MW, Touchstone DA, Kaul S. Importance of two-dimensional echocardiographic assessment of left ventricular systolic function in patients presenting to the emergency room with cardiac-related symptoms. *Circulation* 1991;**84**:1615-24.
60. Kaul S, Senior R, Firschke C, Wang XQ, Lindner J, Villanueva FS et al. Incremental value of cardiac imaging in patients presenting to the emergency department with chest pain and without ST-segment elevation: a multicenter study. *Am Heart J* 2004;**148**:129-36.
61. Kontos MC, Hinchman D, Cunningham M, Miller JJ, Cherif J, Nixon JV. Comparison of contrast echocardiography with single-photon emission computed tomographic myocardial perfusion imaging in the evaluation of patients with possible acute coronary syndromes in the emergency department. *Am J Cardiol* 2003;**91**:1099-102.
62. Tsutsui JM, Xie F, O'Leary EL, Elhendy A, Anderson JR, McGrain AC et al. Diagnostic accuracy and prognostic value of dobutamine stress myocardial contrast echocardiography in patients with suspected acute coronary syndromes. *Echocardiography* 2005;**22**:487-95.
63. Tong KL, Kaul S, Wang XQ, Rinkevich D, Kalvaitis S, Belcik T et al. Myocardial contrast echocardiography versus Thrombolysis In Myocardial Infarction score in patients presenting to the emergency department with chest pain and a nondiagnostic electrocardiogram. *J Am Coll Cardiol* 2005;**46**:920-7.
64. Rinkevich D, Kaul S, Wang X-Q et al. Regional left ventricular perfusion and function in patients presenting to the emergency department with chest pain and no ST-segment elevation. *Eur Heart J* 2005;**26**:1606-11.
65. Jeetley P, Burden L, Greaves K, Senior R. Prognostic value of myocardial contrast echocardiography in patients presenting to hospital with acute chest pain and negative troponin. *Am J Cardiol* 2007;**99**:1369-73.
66. Ragosta M, Camarano GP, Kaul S, Powers E, Sarembock IJ, Gimble LW. Microvascular integrity indicates myocellular viability in patients with recent myocardial infarction: new insights using myocardial contrast echocardiography. *Circulation* 1994;**89**:2562-9.
67. Shimoni S, Frangogiannis NG, Aggeli CJ et al. Microvascular structural correlates of myocardial contrast echocardiography in patients with coronary artery disease and left ventricular dysfunction: implications for the assessment of myocardial hibernation. *Circulation* 2002;**108**:950-6.
68. Coggins MP, Sklenar J, Le DE, Wei K, Lindner JR, Kaul S. Noninvasive prediction of ultimate infarct size at the time of acute coronary occlusion based on the extent and magnitude of collateral-derived myocardial blood flow. *Circulation* 2001;**104**:2471-7.
69. Lafitte S, Higashiyama A, Masugata H, Peters B, Strachan M, Kwan OL et al. Contrast echocardiography can assess risk area and infarct size during coronary occlusion and reperfusion: experimental validation. *J Am Coll Cardiol* 2002;**39**:1546-54.
70. Janardhanan R, Moon JC, Pennell DJ, Senior R. Myocardial contrast echocardiography accurately reflects transmural extent of myocardial necrosis and predicts contractile reserve after acute myocardial infarction. *Am Heart J* 2005;**149**:355-62.
71. Choi EY, Seo HS, Park S et al. Prediction of transmural extent of infarction with contrast echocardiographically derived index of myocardial blood flow and myocardial blood volume fraction: comparison with contrast-enhanced magnetic resonance imaging. *J Am Soc Echocardiogr* 2006;**19**:1211-9.
72. Hickman M, Burden L, Senior R. Resting myocardial blood flow not myocardial blood flow reserve predicts hibernating myocardium: A quantitative myocardial contrast echocardiography study. *J Am Coll Cardiol* 2007;**49**:131A.
73. Senior R, Swinburn JM. Incremental value of myocardial contrast echocardiography for the prediction of recovery of function in dobutamine nonresponsive myocardium early after acute myocardial infarction. *Am J Cardiol* 2003;**91**:397-402.
74. Shimoni S, Frangogiannis NG, Aggeli CJ et al. Identification of hibernating myocardium with quantitative intravenous myocardial contrast echocardiography: comparison with dobutamine echocardiography and thallium-201 scintigraphy. *Circulation* 2003;**107**:538-44.
75. Greaves K, Dixon SR, Fejka M, O'Neill WW, Redwood SR, Marber MS et al. Myocardial contrast echocardiography is superior to other known modalities for assessing myocardial reperfusion after acute myocardial infarction. *Heart* 2003;**89**:139-44.
76. Bolognese L, Carrabba N, Parodi G et al. Impact of microvascular dysfunction on left ventricular remodeling and long-term clinical outcome after primary coronary angioplasty for acute myocardial infarction. *Circulation* 2004;**109**:1121-6.
77. Galiuto L, Garramone B, Scarà A, Rebuzzi A, Crea F, La Torre G et al. The extent of microvascular damage during myocardial contrast echocardiography is superior to other known indexes of post-infarct reperfusion in predicting left ventricular remodeling: results of the multicenter AMICI study. *J Am Coll Cardiol* 2008;**51**:552.
78. Ito H, Maruyama A, Iwakura K, Takiuchi S, Masuyama T, Hori M et al. Clinical implications of the 'no reflow' phenomenon. A predictor of complications and left ventricular remodeling in reperfused anterior wall myocardial infarction. *Circulation* 1996;**93**:223-8.
79. Khumri T, Nayyar S, Idupulapati M, Magalski A, Stoner C, Kusnetzky L et al. Usefulness of Myocardial Contrast Echocardiography in Predicting Late Mortality in Patients With Anterior Wall Acute Myocardial Infarction. *Am J Cardiol* 2006;**98**:1150-5.
80. Dwivedi G, Janardhanan R, Hayat S, Swinburn J M, Senior R. Prognostic value of myocardial viability detected by myocardial contrast echocardiography early after acute myocardial infarction. *J Am Coll Cardiol* 2007;**50**:327-34.
81. Hayat SA, Senior R. Myocardial contrast echocardiography in ST elevation myocardial infarction: ready for prime time? *Eur Heart J* 2008;**29**:299-314.
82. Wei K, Ragosta M, Thorpe J, Coggins M, Moos S, Kaul S. Non-invasive quantification of coronary blood flow reserve in humans using myocardial contrast echocardiography. *Circulation* 2001;**103**:2560-5.

83. Peltier M, Vancraeynest D, Pasquet A, Ay T, Roelants V, D'hondt AM *et al.* Assessment of the physiologic significance of coronary disease with dipyridamole real-time myocardial contrast echocardiography. Comparison with technetium-99m sestamibi single-photon emission computed tomography and quantitative coronary angiography. *J Am Coll Cardiol* 2004;**43**:257–64.
84. Vogel R, Indermuhle A, Reinhardt J, Meier P, Siegrist PT, Namdar M *et al.* The quantification of absolute myocardial perfusion in humans by contrast echocardiography. *J Am Coll Cardiol* 2005;**45**:754–62.
85. Senior R, Janardhanan R, Jeetley P, Burden L. Myocardial contrast echocardiography for distinguishing ischemic from nonischemic first-onset acute heart failure: insights into the mechanism of acute heart failure. *Circulation* 2005;**112**:1587–93.
86. Hayat SA, Dwivedi G, Jacobsen A, Kinsey C, Senior R. Effects of left bundle branch block on cardiac structure, function perfusion and perfusion reserve: implications for myocardial contrast echocardiography versus radionuclide perfusion imaging for the detection of coronary artery disease. *Circulation* 2008;**117**:1832–41.
87. Janardhanan R, Senior R. Accuracy of dipyridamole myocardial contrast echocardiography for the detection of residual stenosis of the infarct-related artery and multivessel disease early after acute myocardial infarction. *J Am Coll Cardiol* 2004;**43**:2247–52.
88. Moir S, Haluska BA, Jenkins C, McNab D, Marwick TH. Myocardial blood volume and perfusion reserve responses to combined dipyridamole and exercise stress: a quantitative approach to contrast stress echocardiography. *J Am Soc Echocardiogr* 2005;**18**:1187–93.
89. Sicari R, Nihoyannopoulos P, Evangelista A, Kasprzak J, Lancellotti P, Poldermans D *et al.* Stress echocardiography expert consensus statement: European Association of Echocardiography (EAE) (a registered branch of the ESC). *Eur J Echocardiogr* 2008;**9**:415–37.
90. Senior R, Dwivedi G, Hayat S, Lim TH. Clinical benefits of contrast-enhanced echocardiography during rest and stress examinations. *Eur J Echocardiogr* 2005;**6**:S6–S13.
91. Olszewski R, Timperley J, Szmigielski C, Monaghan M, Nihoyannopoulos P, Senior R *et al.* The clinical applications of contrast echocardiography. *Eur J Echocardiogr* 2007;**8**:S13–S23.
92. Rakhit DJ, Becher H, Monaghan M, Nihoyannopoulos P, Senior R. The clinical applications of myocardial contrast echocardiography. *Eur J Echocardiography* 2007;**8**:S24–9.
93. Tsutsui JM, Xie F, McGrain, Mahrour H, Hankins J, O'Leary EL *et al.* Comparison of low-mechanical index pulse sequence schemes for detecting myocardial perfusion abnormalities during vasodilator stress echocardiography. *Am J Cardiol* 2005;**95**:565–70.
94. Cohen JL, Cheirif J, Segar DS, Gillam LD, Gottdiener JS, Hausnerova E *et al.* Improved left ventricular endocardial border delineation and opacification with Optison (FS069), a new echocardiographic contrast agent. Results of a phase III multicenter trial. *J Am Coll Cardiol* 1998;**32**:746–52.
95. Senior R, Andersson O, Caidahl K, Carlens P, Herregods MC, Jenni R *et al.* Enhanced left ventricular endocardial border delineation with an intravenous injection of SonoVue, a new echocardiographic contrast agent: a European multicenter study. *Echocardiography* 2000;**17**:705–11.
96. Kitzman DW, Goldman ME, Gillam LD, Cohen JL, Aurigemma GP, Gottdiener JS. Efficacy and safety of the novel ultrasound contrast agent perflutren (Definity) in patients with suboptimal baseline left ventricular echocardiographic images. *Am J Cardiol* 2000;**86**:669–74.
97. Nguyen TT, Dhond MR, Sabapathy R, Bommer WJ. Contrast microbubbles improve diagnostic yield in ICU patients with poor echocardiographic windows. *Chest* 2001;**120**:1287–92.
98. Nanda NC, Wistran DC, Karlsberg RP, Hack TC, Smith WB, Foley DA *et al.* Multicenter evaluation of SonoVue for improved endocardial border delineation. *Echocardiography* 2002;**19**:27–36.
99. Rizzo M, Vono MC, Toncelli L, Pecagna P, Manetti P, Stefani L *et al.* The feasibility and usefulness of contrast exercise echocardiography for the assessment of left ventricular function in master athletes. *Eur J Echocardiogr* 2005;**6**:24–30.
100. Tsutsui JM, Elhendy A, Xie F, O'Leary EL, McGrain AC, Porter TR. Safety of dobutamine stress real-time myocardial contrast echocardiography. *J Am Coll Cardiol* 2005;**45**:1235–42.
101. Wake R, Takeuchi M, Yoshitani H, Miyazaki C, Otani S, Yoshiyama M *et al.* Role of contrast-enhanced dobutamine stress echocardiography in predicting outcome in patients with known or suspected coronary artery disease. *Echocardiography* 2006;**23**:642–9.
102. Korosoglou G, Dubart AE, DaSilva KG, Labadze N, Hardt S, Hansen A *et al.* Real-time myocardial perfusion imaging for pharmacologic stress testing: added value to single photon emission computed tomography. *Am Heart J* 2006;**151**:131–8.
103. Ikonomidis I, Holmes E, Narbuold H, Bolstad B, Muan B, Nihoyannopoulos P. Left ventricular wall motion assessment and Endocardial border delineation after intravenous injection of Infuson™ during dobutamine stress echocardiography. *Coronary Artery Disease* 1998;**9**:567–76.
104. Bhatia V, Senior R. Contrast echocardiography in clinical practice. Evidence so far. *J Am Soc Echocardiogr* 2008;**21**:409–16.
105. Chiou KR, Huang WC, Lin SL, Hsieh PL, Liu CP, Tsay DG *et al.* Real-time dobutamine stress myocardial contrast echocardiography for detecting coronary artery disease: correlating abnormal wall motion and disturbed perfusion. *Can J Cardiol* 2004;**20**:1237–43.
106. Cwajg J, Xie F, O'Leary E, Kricsfeld D, Ditttrich H, Porter TR. Detection of angiographically significant coronary artery disease with accelerated intermittent imaging after intravenous administration of ultrasound contrast material. *Am Heart J* 2000;**139**:675–83.
107. Elhendy A, O'Leary EL, Xie F, McGrain AC, Anderson JR, Porter TR. Comparative accuracy of real-time myocardial contrast perfusion imaging and wall motion analysis during dobutamine stress echocardiography for the diagnosis of coronary artery disease. *J Am Coll Cardiol* 2004;**44**:2185–91.
108. Jeetley P, Hickman M, Kamp O, Lang RM, Thomas JD, Vannan MA *et al.* Myocardial contrast echocardiography for the detection of coronary artery stenosis: a prospective multicenter study in comparison with single-photon emission computed tomography. *J Am Coll Cardiol* 2006;**47**:141–5.
109. Karavidas AI, Matsakas EP, Lazaros GA, Brestas PS, Avramidis DA, Zacharoulis AA *et al.* Comparison of myocardial contrast echocardiography with SPECT in the evaluation of coronary artery disease in asymptomatic patients with LBBB. *Int J Cardiol* 2006;**112**:334–40.
110. Lin SL, Chiou KR, Huang WC, Peng NJ, Tsay DG, Liu CP. Detection of coronary artery disease using real-time myocardial contrast echocardiography: a comparison with dual-isotope resting thallium-201/stress technetium-99m sestamibi single-photon emission computed tomography. *Heart Vessels* 2006;**21**:226–35.
111. Malm S, Frigstad S, Torp H, Wiseth R, Skjarpe T. Quantitative adenosine real-time myocardial contrast echocardiography for detection of angiographically significant coronary artery disease. *J Am Soc Echocardiogr* 2006;**19**:365–72.
112. Winter R, Gudmundsson P, Willenheimer R. Real-time perfusion adenosine stress echocardiography in the coronary care unit: a feasible bedside tool for predicting coronary artery stenosis in patients with acute coronary syndrome. *Eur J Echocardiogr* 2005;**6**:31–40.
113. Sbrano JC, Tsutsui JM, Andrade JL, Carlos Nicolau J, Meneghetti JC, Franchini Ramires J *et al.* Detection of functional recovery using low-dose dobutamine and myocardial contrast echocardiography after acute myocardial infarction treated with successful thrombolytic therapy. *Echocardiography* 2005;**22**:496–502.
114. Aggeli C, Stefanadis C, Bonou M, Pitsavos C, Theocharis C, Roussakis G *et al.* Prediction of functional recovery of hibernating myocardium using harmonic power Doppler imaging and dobutamine stress echocardiography in patients with coronary artery disease. *Am J Cardiol* 2003;**91**:1415–20.
115. Hillis GS, Mulvagh SL, Pellikka PA, Hagen ME, Gunda M, Wright RS *et al.* Comparison of intravenous myocardial contrast echocardiography and low-dose dobutamine echocardiography for predicting left ventricular functional recovery following acute myocardial infarction. *Am J Cardiol* 2003;**92**:504–8.
116. Main ML, Magalski A, Chee NK, Coen MM, Skolnick DG, Good TH. Full-motion pulse inversion power Doppler contrast echocardiography differentiates stunning from necrosis and predicts recovery of left ventricular function after acute myocardial infarction. *J Am Coll Cardiol* 2001;**38**:1390–4.
117. Swinburn JM, Senior R. Real time contrast echocardiography—a new bedside technique to predict contractile reserve early after acute myocardial infarction. *Eur J Echocardiogr* 2002;**3**:95–9.
118. Hillis GS, Mulvagh SL, Gunda M, Hagen ME, Reeder GS, Oh JK. Contrast echocardiography using intravenous octafluoropropane and real-time perfusion imaging predicts functional recovery after acute myocardial infarction. *J Am Soc Echocardiogr* 2003;**16**:638–45.
119. Lepper W, Kamp O, Vanoverschelde JL, Franke A, Sieswerda GT, Pasquet A *et al.* Intravenous myocardial contrast echocardiography predicts left ventricular remodeling in patients with acute myocardial infarction. *J Am Soc Echocardiogr* 2002;**15**:849–56.

120. Hickman M, Janardhanan R, Dwivedi G, Burden L, Senior R. Clinical significance of perfusion techniques utilising different physiological mechanisms to detect myocardial viability: a comparative study with myocardial contrast echocardiography and single photon emission computed tomography. *Int J Cardiol* 2007;114:139–40.
121. Janardhanan R, Swinburn JM, Greaves K, Senior R. Usefulness of myocardial contrast echocardiography using low-power continuous imaging early after acute myocardial infarction to predict late functional left ventricular recovery. *Am J Cardiol* 2003;92:493–7.
122. Main ML, Magalski A, Chee NK, Coen MM, Skolnick DG, Good TH. Full-motion pulse inversion power Doppler contrast echocardiography differentiates stunning from necrosis and predicts recovery of left ventricular function after acute myocardial infarction. *J Am Coll Cardiol* 2001;38:1390–4.
123. Agati L, Voci P, Autore C *et al.* Combined use of dobutamine echocardiography and myocardial contrast echocardiography in predicting regional dysfunction recovery after coronary revascularization in patients with recent myocardial infarction. *Eur Heart J* 1997;18:771–9.
124. Huang WC, Chiou KR, Liu CP *et al.* Comparison of real-time contrast echocardiography and low-dose dobutamine stress echocardiography in predicting the left ventricular functional recovery in patients after acute myocardial infarction under different therapeutic intervention. *Int J Cardiol* 2005;104:81–91.
125. Abe Y, Muro T, Sakanoue Y *et al.* Intravenous myocardial contrast echocardiography predicts regional and global left ventricular remodelling after acute myocardial infarction: comparison with low dose dobutamine stress echocardiography. *Heart* 2005;91:1578–83.
126. Korosoglou G, Labadze N, Giannitsis E *et al.* Usefulness of real-time myocardial perfusion imaging to evaluate tissue level reperfusion in patients with non-ST-elevation myocardial infarction. *Am J Cardiol* 2005;95:1033–8.
127. Binder T, Assayag P, Baer F, Flachskampf F, Kamp O, Nienaber C *et al.* NC100100, a new echo contrast agent for the assessment of myocardial perfusion—safety and comparison with MIBI SPECT in a randomised multicentre study. *Clin Cardiol* 1999;22:273–82.
128. Jucquois I, Nihoyannopoulos P, D'Hontdt A-M, Roelants V, Robert A, Melin JA *et al.* Comparison of myocardial contrast echocardiography with NC100100 and Tc-99m sestamibi single photon emission computed tomography for detection of resting myocardial perfusion abnormalities in patients with previous myocardial infarction. *Heart* 2000;83:518–24.