

ECG-based Diagnoses in Cardiovascular Emergencies

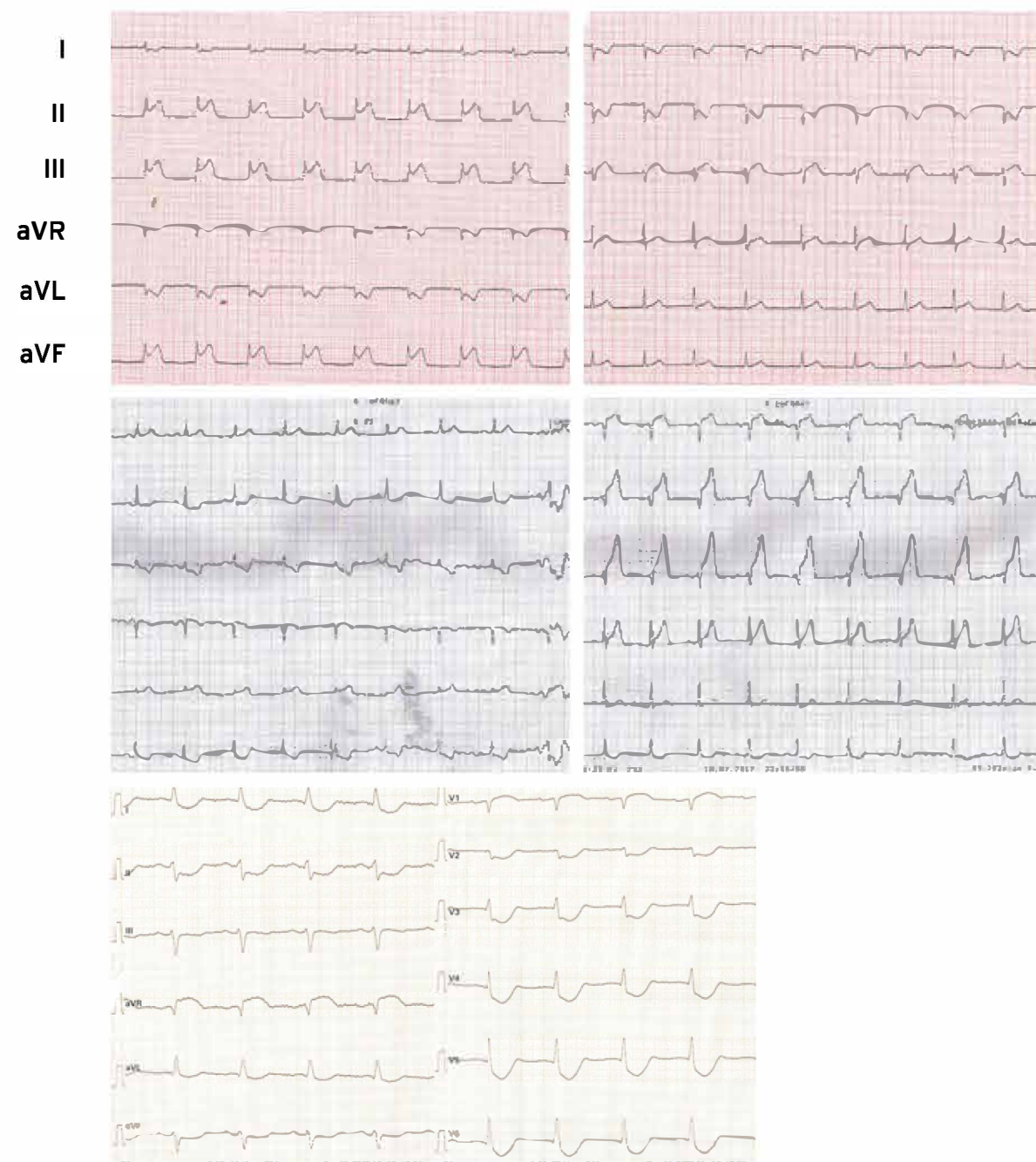
Disclaimer: All shown ECGs are only examples of the typical diseases as they might be encountered in everyday clinical practice. Some patients might show different diseases although the ECG looks similar

First ECG must be done on first contact with interpretation on scene by trained emergency personal or via telemedicine.

In all patients arriving at the emergency department with a suspect of acute coronary syndrome the first ECG must be recorded within 10 minutes after patient arrival

ST Elevation Myocardial Infarction (STEMI)

- ST-segment elevation in at least two contiguous leads $>0.25/ >0.2mV$ in men $<40/>40$ years or $0.15mV$ in women in leads V2/V3 and/or $0.1mV$ in other leads. Additional leads should always be included with V7 through V9 and V3r through V4r
- ST-segment depression in V1-V3 and positive terminal T-Wave record leads V7-V9 to identify ST-segment elevation $\geq 0.1mV$
- In inferior (right coronary artery) myocardial infarction record leads V3r and V4r to identify right ventricular involvement
- In left bundle branch block concordant ST elevation (leads with positive QRS deflection) seems to be the best indicator
- Presence of ST-depression in eight or more surface leads together with ST-elevation in aVR and/or V1 suggests left main disease



Ventricular arrhythmias/Cardiac Arrest


Ventricular fibrillation

- Irregular deflections of varying amplitude
- No P-waves, QRS complexes or T-waves identifiable on the ECG

Ventricular tachycardia: Regular, broad QRS complexes

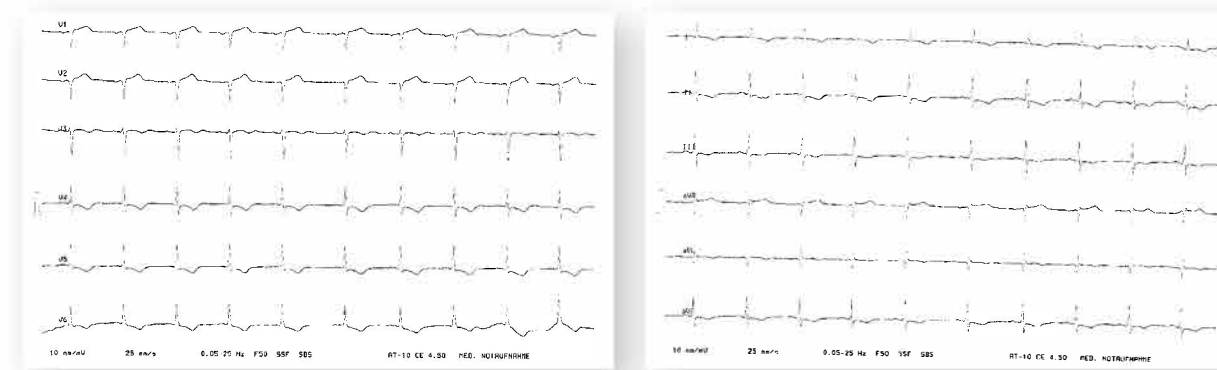
Pulseless electric activity/asystole

- Pulseless electric activity is defined as any electrical cardiac activity expected to generate pulsatile circulation but the patient has signs of cardiac arrest and no palpable pulse
- Asystole is characterized by an ECG without any electrical activity



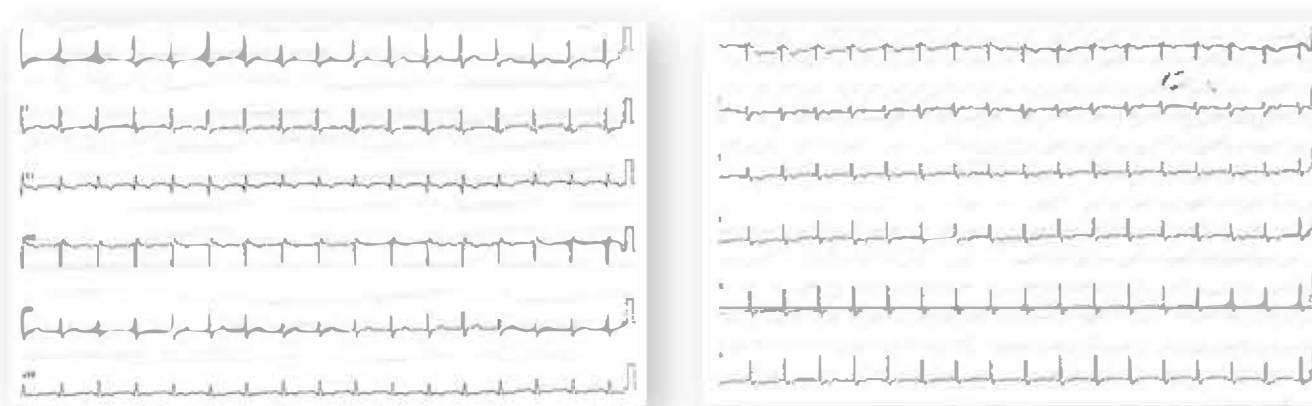
Non-ST Elevation Myocardial Infarction (NSTEMI)

- No pathological ECG changes in 1/3 of patients and if normal additional leads with V7 through V9 and V3r through V4r should be considered
- Typical signs include ST-depression, T-wave inversion and transient ST-segment elevations
- Obtain additional ECGs during monitoring i.e. recurrent symptoms
- ECG confounders like left BBB or paced rhythm corrupt ECG based diagnosis



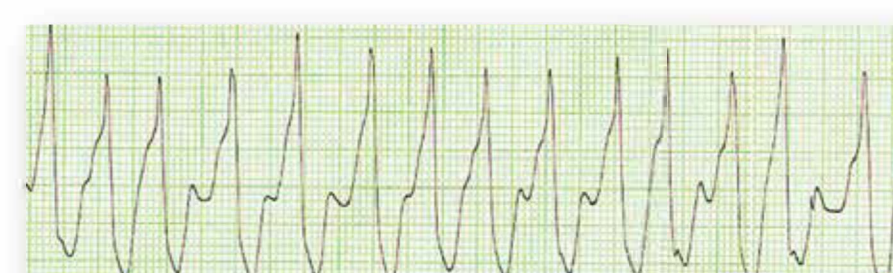Pulmonary Embolism

- S1Q3T3 sign indicate acute volume and/ or pressure overload of the right ventricle
- New complete or incomplete right BBB with rightward shift of the QRS axis
- ST segment elevation in aVR and V1, T-wave inversion in leads V1-V4
- Sinustachycardia or atrial fibrillation/ atrial flutter

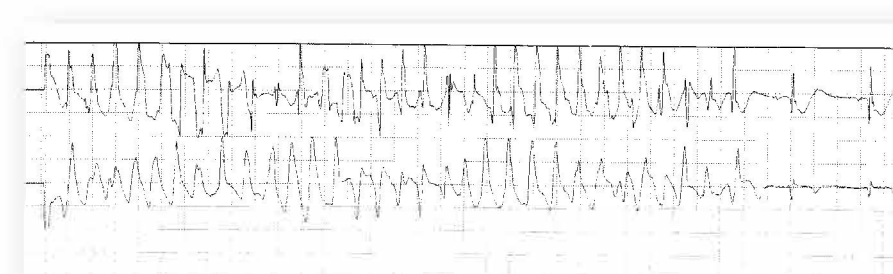


Rare important diagnoses

- Fast, broad and irregular tachycardias are characterized by a wide QRS complex tachycardia, right-bundle branch block, right superior axis deviation and varying RR intervals
- Fast Broad Irregular tachycardia are due to atrial fibrillation with antegrade conduction via left posterolateral pathway
- Torsades de pointes tachycardia is a form of polymorphic ventricular tachycardia occurring in the context of QT prolongation



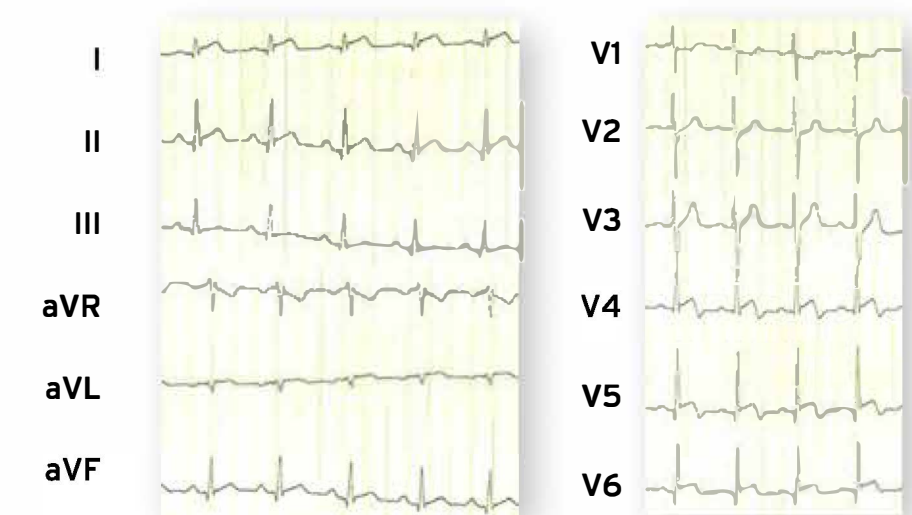
Fast Broad Irregular tachycardia



Torsades de pointes tachycardia

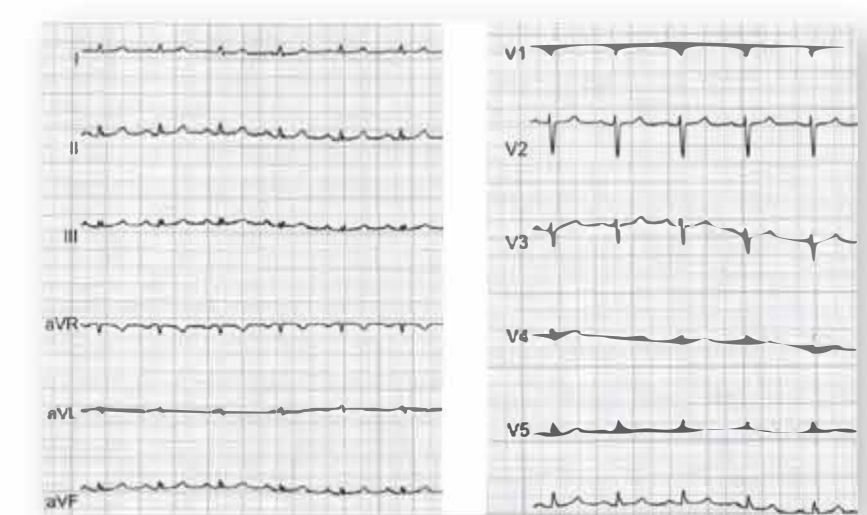
Myocarditis

- Most commonly presence of non-specific ST-segment and T-wave changes often with sinus tachycardia
- QRS/ QT prolongation and AV conduction defects
- Diffuse T-wave inversion or features of pericarditis
- Ventricular tachycardia



Pericarditis/Pericardial effusion

- Widespread concave ST-elevation and PR-depression found in both the limb leads and chest leads
- Reciprocal ST-depression and PR-elevation in lead aVR and/or V1
- Presence of sinus tachycardia (due to pain or pericardial effusion)
- Low QRS voltage, sinus tachycardia and electrical alternans suggest presence of pericardial effusion



Bradyarrhythmias/ Atrioventricular Block

- Complete heart block (3rd degree AV Block) with ECG has independent ventricular and atrial rates (AV dissociation)
- ECG shows a junctional or ventricular escape rhythm in AV block 3

